

Locametz[®] Educational Material for HCPs

Gallium (⁶⁸Ga) gozetotide image interpretation training

▼ This medicinal product is subject to additional monitoring.
This will allow quick identification of new safety information.
Healthcare professionals are asked to report any suspected adverse reactions.

Part of risk management plan v1.3.

Date of Fimea approval: 17.3.2023

Version 1.0

October 2022 | AAA-NP-GL-0334-22

01/2023 | Locametz_2023_FIEN_1



LOCAL REPRESENTATIVE IN FINLAND

S AHLÉN MEDICAL AB
Cylindervägen 18, PLAN 5
131 52 Nacka Strand, SWEDEN
info@samnordic.se
+46 8 720 58 22
www.samnordic.se

Marketing authorisation holder:
Novartis Europharm Limited
Vista Building
Elm Park, Merriem Road
Dublin 4, Ireland



Adverse drug reactions

Reporting suspected adverse reactions after authorisation of the medicinal product is important. It allows continued monitoring of the benefit/risk balance of the medicinal product.

Please report any suspected adverse reactions to Locametz, to:

Fimea

Lääkealan turvallisuus- ja kehittämiskeskus Fimea
Lääkkeiden haittavaikutusrekisteri
PL 55
00034 FIMEA
www.fimea.fi

Or:

Novartis Finland Oy

Metsänneidonkuja 10
02130 Espoo
Phone: 010 6133 200
www.novartis.fi
www.novartis.com/report

Locametz Summary of Product Characteristics

https://www.ema.europa.eu/en/documents/product-information/locametz-epar-product-information_fi.pdf

Contents

05	<u>Gallium (^{68}Ga) Gozetotide Image Interpretation Training: Purpose of the Document</u>	
06	<u>Introduction to Gallium (^{68}Ga) Gozetotide: Locametz[®] Indications</u>	
07	<u>Legal Disclosures</u>	
08	<u>Biochemical Basics</u>	
	• Chemical Structure	08
	• PSMA	09
	• Mechanism of Uptake	10
11	<u>Patient Administration and Scanning Protocol</u>	
	• Patient Preparation	11
	• Injection Recommendations	13
	• Scanning Protocol	14
16	<u>Image Reading and Interpretation Guidelines</u>	
	• Locametz [®] Special Warnings and Precautions for Use	16
	• Guidelines and Practical Tips	17
	• PSMA Visual Assessment Scoring Scale	19
20	<u>PSMA PET in the Context of Other Imaging Modalities and Histopathology</u>	

Contents

21 **Interpretation of Gallium (^{68}Ga) Gozetotide PET Scans in Different Use Scenarios, and Comprehensive Case Study Reviews**

• <u>Physiological Distribution of Gallium (^{68}Ga) Gozetotide</u>	22
• <u>Primary Staging of Patients With High-Risk PCa Prior to Primary Curative Therapy</u>	24
– <u>PCa - Unifocal Tumor</u>	25
– <u>PCa - Multifocal Tumor</u>	26
– <u>PCa - Multifocal Tumor With Pelvic Lymph Node Metastases</u>	27
– <u>PCa - Multifocal Tumor With Distant Metastases</u>	28
• <u>Suspected PCa Recurrence in Patients With Increasing Levels of Serum Prostate-Specific Antigen (PSA) After Primary Curative Therapy</u>	29
– <u>PCa - Local Recurrence</u>	30
– <u>PCa - Local Recurrence (Colon Infiltration)</u>	33
– <u>Local Lymph Nodes (Iliac)</u>	34
– <u>Distant Lymph Nodes (Retroperitoneal)</u>	35
– <u>Distant Lymph Nodes (Mediastinal)</u>	37
– <u>Distant Lymph Nodes (Supraclavicular – Virchow's Node)</u>	38
– <u>Pulmonary Metastases</u>	39
– <u>Solitary Bone Metastases</u>	40
– <u>Polytopic Bone Metastasis</u>	41
– <u>Disseminated Bone Metastases and Diffuse Bone Marrow Infiltration</u>	42
– <u>Single Hepatic Metastasis</u>	43
• <u>Identification of Patients With PSMA-positive Metastatic Castration-resistant PCa for Whom PSMA-targeted Therapy is Indicated</u>	44
– <u>Case for the Identification of a Patient for Whom PSMA-targeted Therapy Is Indicated</u>	45

Contents

47 **Rare Locations**

• <u>Penis Metastasis</u>	48
• <u>Metastasis in the Left Orbita</u>	48
• <u>Metastasis of the Left Mamma</u>	48
• <u>Metastasis of the Skin</u>	49
• <u>Brain Ventricular Metastasis</u>	49
• <u>Metastasis of the Right Adrenal Gland</u>	49

50 **PSMA Expression in Other Malignant Tumors**

• <u>Adenoid Cystic Carcinoma (ACC) and Salivary Duct Carcinoma</u>	51
• <u>Hepatocellular Carcinoma (HCC)</u>	52
• <u>Sarcoma</u>	53

54 **Pitfalls**

• <u>Ganglia of the Sympathetic Trunk</u>	55
• <u>Sarcoidosis</u>	56
• <u>Accessory Salivary Gland/Tissue</u>	57
• <u>Urine Activity (ureter)</u>	58
• <u>Urine Contamination</u>	59
• <u>Benign Bone Lesions</u>	60

61 **Self-assessment Test**

Gallium (^{68}Ga) Gozetotide Image Interpretation Training: Purpose of the Document

Gallium (^{68}Ga) gozetotide image interpretation training has been developed as an additional resource to help you familiarize yourself with techniques for the safe and effective usage of gallium (^{68}Ga) gozetotide.

This training provides essential information on the risks associated with gallium (^{68}Ga) gozetotide PET imaging interpretation errors.

Disclaimer:

- To make some findings obvious at first glance, the windowing of the figures has been adjusted (where appropriate) in an area that varies from the clinical workflow
- Whole body images of patients represent 2D screenshots from MIPs. The position (line of sight) has been clarified and is indicated using the following abbreviations:
 - A: from anterior (front)
 - L: from left
 - R: from right
 - P: from posterior (back)
- The interpretation of all the presented cases was consistent among three readers. Cases were initially assessed by a nuclear medicine specialist and interpretation was confirmed by two additional specialists (a nuclear medicine physician and a radiologist)

Introduction of Gallium (^{68}Ga) Gozetotide: Locametz[®] Indications

▼ This medicinal product is subject to additional monitoring. This will allow quick identification of new safety information. Healthcare professionals are asked to report any suspected adverse reactions.

This medicinal product is for diagnostic use only.

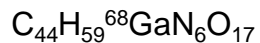Locametz[®], after radiolabelling with gallium-68, is indicated for the detection of prostate-specific membrane antigen (PSMA)-positive lesions with positron emission tomography (PET) in adults with prostate cancer (PCa) in the following clinical settings:

- Primary staging of patients with high-risk PCa prior to primary curative therapy
- Suspected PCa recurrence in patients with increasing levels of serum prostate-specific antigen (PSA) after primary curative therapy
- Identification of patients with PSMA-positive progressive metastatic castration-resistant prostate cancer (mCRPC) for whom PSMA-targeted therapy is indicated

Legal Disclosures

- Expert recommendations in accordance with the EAU-EANM-STRO-ESUR-ISUP-SIOG guidelines on PCa
- Local law, national regulations, and guidelines are not affected by the information presented; these should be taken into consideration
- The gallium (^{68}Ga) gozetotide image interpretation training (Locametz® educational material for HCPs) has been developed as an additional resource to help you familiarize yourself with techniques for the safe and effective usage of gallium (^{68}Ga) gozetotide
- Responsibility of the accurate and timely acquisition, and interpretation of images using gallium (^{68}Ga) gozetotide PET/CT scanning rests with the nuclear medicine physician or radiologist supervising the PET/CT imaging facility
- The gallium (^{68}Ga) gozetotide image interpretation training is not intended as a substitute for the independent medical judgment of the physician(s) responsible for the individual patient's management, nor is it a guarantee of any specific clinical results
- The Locametz® Educational Material for HCPs were prepared with support of Dr. Himmen and Dr. Sandach and reviewed by Dr. Herrmann from the University Hospital Essen.

Chemical Structure of Gallium (⁶⁸Ga) Gozetotide



European Pharmacopoeia 10.4 04/2021:3044.

Biochemical Basics

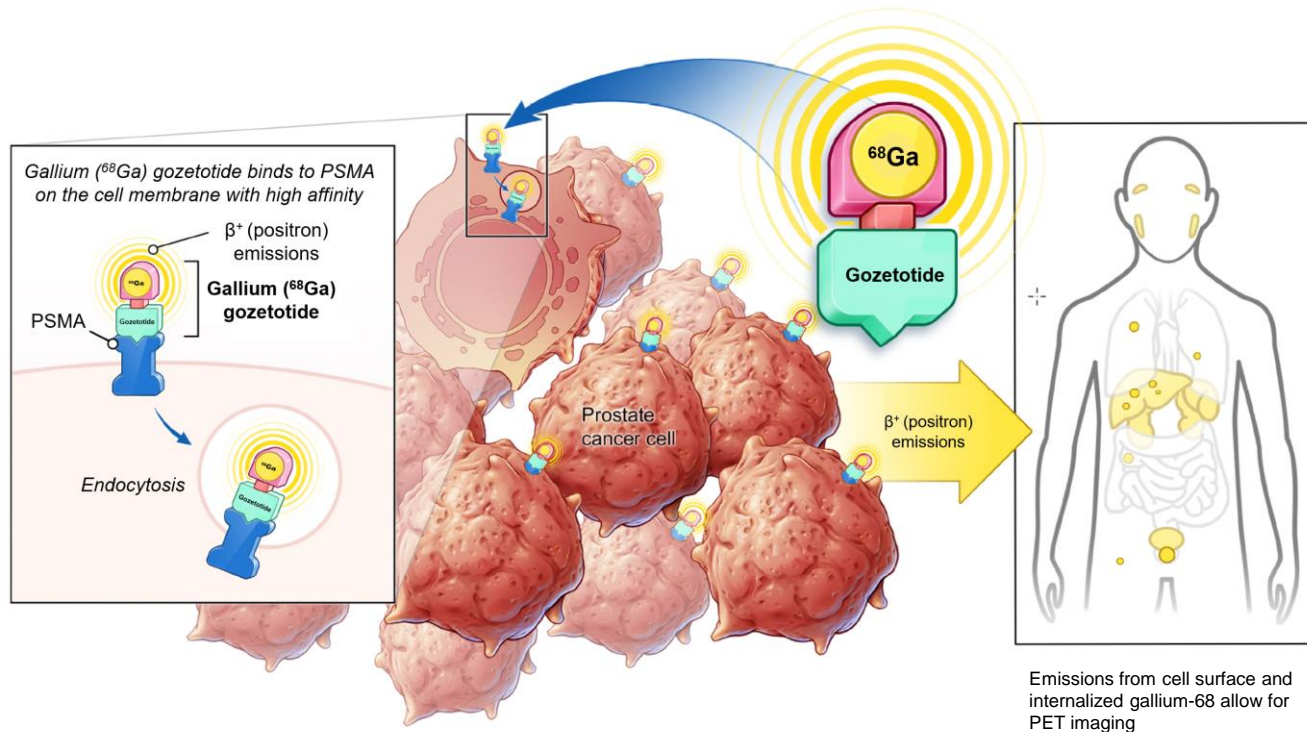
PSMA

- Glutamate carboxypeptidase II (GCPII)
 - Hydrolysis of N-acetylaspartylglutamate (NAAG) to glutamate and N-acetylaspartate (NAA)
- Cell surface protein, mainly expressed in:
 - Prostate epithelium
 - Proximal tubules of the kidney(s)
 - Brush border of the small intestine
 - Ganglia of the nervous system
 - Salivary and lacrimal glands
 - Liver and spleen
- PSMA expression in PCa is up to 100- to 1000-fold higher than in physiological prostate tissue
 - Function in prostate widely unknown; suggested involvement in the neuroendocrine regulation of prostate growth and differentiation
 - Expression correlates with cancer aggressiveness

Biochemical Basics

Mechanism of Uptake

1. IV injection
2. Transport to tumor site via the blood stream
3. Binding to PSMA on the cell surface
4. Internalization via endocytosis



Emissions from cell surface and internalized gallium-68 allow for PET imaging

Patient Administration and Scanning Protocol

Patient Preparation

- The following documents should be provided for proper scan interpretation:
 - Previous reports, including recent lab results
 - PSA-kinetics, gleason score
 - Kidney and thyroid results, if iodinated contrast-enhanced CT is planned
 - Recent history of PCa-specific medications and treatments
- Additional information that should be provided:
 - Information about duration of the procedure (2–4 hours, depending the site-specific protocol)
 - Fasting is not required; most medications can be taken prior to scan
- Prior appointment confirmation is recommended in order to reduce down-time

Patient Administration and Scanning Protocol

Patient Preparation

- Patient preparation:
 - Patients should be well hydrated prior to gallium (^{68}Ga) gozetotide administration and should be advised to void immediately prior to, and frequently during the first hours after image acquisition in order to reduce radiation exposure
- Injection:
 - Recommended dosage: 111–259 MBq
 - Handle gallium (^{68}Ga) gozetotide injection with appropriate safety measures to minimize radiation exposure

Patient Administration and Scanning Protocol

Injection Recommendation

- Aseptic technique and radiation shielding should be used when withdrawing and administering gallium (^{68}Ga) gozetotide solution for injection
- Prior to use, visually inspect the prepared gallium (^{68}Ga) gozetotide solution for injection behind a lead glass shield for radioprotection purposes. Only solutions that are clear, colourless and without undissolved matter should be used
- After reconstitution and radiolabelling, gallium (^{68}Ga) gozetotide solution for injection can be diluted with water for injections or sodium chloride 9 mg/mL (0.9%) solution for infusion up to a final volume of 10 mL. For the IRE ELiT Galli Ad generator, dilution to a minimum volume of 4 mL is required in order to reduce osmolality
- Using a single dose syringe fitted with a sterile needle (size 21G 23G) and protective shielding, aseptically withdraw the prepared gallium (^{68}Ga) gozetotide solution for injection prior to administration
- The total radioactivity in the syringe should be verified with a dose calibrator immediately before and after gallium (^{68}Ga) gozetotide administration to the patient. The dose calibrator must be calibrated and comply with international standards

Patient Administration and Scanning Protocol

Scanning Protocol

Gallium (^{68}Ga) gozetotide PET image acquisition should be performed by scanning the whole body starting at mid-thigh and proceeding to skull base. PET images should be acquired 50 to 100 minutes after the intravenous administration of gallium (^{68}Ga) gozetotide solution.

Image acquisition start time and duration should be adapted to the equipment used, the patient, and the tumor characteristics in order to obtain the best image quality possible.

Practical recommendations from the authors:

CT scan

- Low dose without contrast agent
- Full dose without contrast agent
- Full dose contrast-enhanced (in accordance with ESUR Guideline)
- Arms should be positioned above head to avoid artifacts
- Depending on clinical requirements, from skull base to mid-thigh (scan direction as per local protocol)

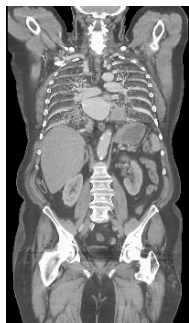
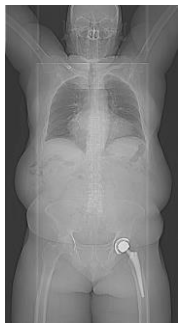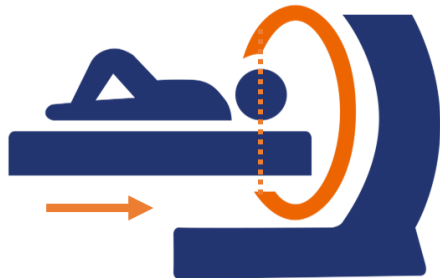
PET scan

- Depending on clinical requirements, from mid-thigh to skull base (coverage identical to CT scan) - scan direction from pelvis to head (scan direction as per local protocol)
- 2–4 min per bed position or equivalent continuous motion
- Reconstruction with and without attenuation correction
- Confirm quality immediately after scan

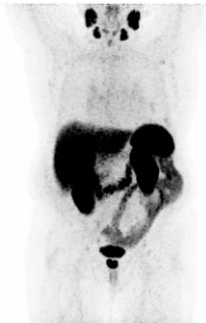Patient Administration and Scanning Protocol

Scanning Protocol

CT-Scan



PET-Scan



Fusion

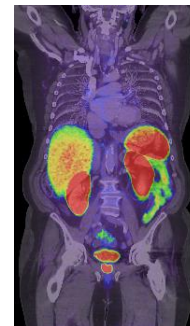
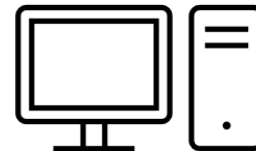


Image Reading and Interpretation Guidelines

Locametz® Special Warnings and Precautions for Use

- PET images with gallium (^{68}Ga) gozetotide should be interpreted by visual assessment. Suspicion of malignant lesions is based on gallium (^{68}Ga) gozetotide uptake in comparison with tissue background
- Gallium (^{68}Ga) gozetotide uptake is not specific to prostate cancer and may occur in normal tissues, other types of cancers and non-malignant processes, potentially leading to false positive findings
- The diagnostic performance of gallium (^{68}Ga) gozetotide may be affected by serum PSA levels, androgen receptor–targeting treatments, disease stage, and size of malignant lymph nodes
- Gallium (^{68}Ga) gozetotide PET images should be interpreted only by readers trained in the interpretation of PET images with gallium (^{68}Ga) gozetotide PET. Findings on gallium (^{68}Ga) gozetotide PET images should always be interpreted in conjunction with and be confirmed by other diagnostic methods (including histopathology) before subsequent change in patient management is initiated.

Image Reading and Interpretation Guidelines

Guidelines and Practical Tips

For detailed instructions on image reading, and interpretation of PET and PSMA PET, please refer to official guidelines, e.g., the joint EANM and SNMMI procedure guidelines.

Practical recommendations from the authors:

- Always check for the patient's full name, date of birth, and the exam date first
- Verify that the correct weight, height, activity, and acquisition time have been entered to avoid false visual uptake and SUV measurements
- Always be mindful of the patient's individual medical history
- Use all series and images you have, both individually and combined: CT/MRI, PET, fusion (and prior exams if available)

Image Reading and Interpretation Guidelines

Guidelines and Practical Tips

Reading tips for the identification of lesions with low or no PSMA expression, which are associated with poor prognosis

- Lymph nodes, parenchymal metastases, and prostate bed/urinary bladder:
 - Careful reading of diagnostic CT
 - In cases of extensive PSMA-positive adenopathy (particularly confluent), look for focal areas of decreased uptake that could be negative nodes
 - Coronal and sagittal views can be particularly helpful for the prostate bed/urinary bladder
- Liver metastases:
 - Active windowing of PET and positioning the liver in the middle of the window
 - Careful reading of diagnostic CT with specific liver windows
- Bone metastases:
 - Careful reading of diagnostic CT on bone and soft tissue windows
 - On PET and fused images, look for mild activity outside margins of bony cortex

Image Reading and Interpretation Guidelines

PSMA Visual Assessment Scoring Scale

- A visual assessment scoring scale for gallium (^{68}Ga) gozetotide has been developed to guide image interpretation
 - For more details on these EANM standardized reporting guidelines as well as flowcharts for systematic classification, please refer to Ceci et al.
-
- A PROMISE criteria is also proposed as a visual concept for the standardized assessment of suspicious lesions based on PSMA expression. The PSMA expression score is formed by the physiological PSMA expression of specific organs. From the composition of the lesions, their PSMA expression and the respective localizations, a miTNM staging can be formed
 - Please refer to Eiber et al. for more details

Visual Score	PSMA expression	Uptake compared to threshold organs
0	No	$X < \text{blood pool}$
1	Low	$\text{Blood pool} \leq X < \text{liver}$
2	Intermediate	$\text{Liver} \leq X < \text{parotid gland}$
3	High	$X \geq \text{parotid gland}$

A practical example on how to use the visual score can be seen in the clinical case: **“Case for the Identification of a Patient for Whom PSMA-Targeted Therapy Is Indicated”**

► CLICK TO PLAY

PSMA PET in the Context of Other Imaging Modalities

- According to proPSMA, PSMA PET/CT has proven to be a superior alternative to conventional imaging modalities (CT and bone scan combined); it outperformed conventional staging in accuracy (92% vs 65%), sensitivity (85% vs 38%), and specificity (98% vs 91%)
- The use of PET/CT fusion leads to better anatomical correlation of findings, resulting in increased accuracy of assessment and reduction in image interpretation errors
- PSMA PET in the context of histopathology:
 - Gallium (^{68}Ga) gozetotide PSMA PET cannot replace histopathology
 - The presence of an accurate histopathology increases the quality of the findings and confidence in the assessment
 - On the other hand, (^{68}Ga) gozetotide PSMA PET can help in the selection of suitable tumor locations for biopsy to ensure the best possible staging and grading

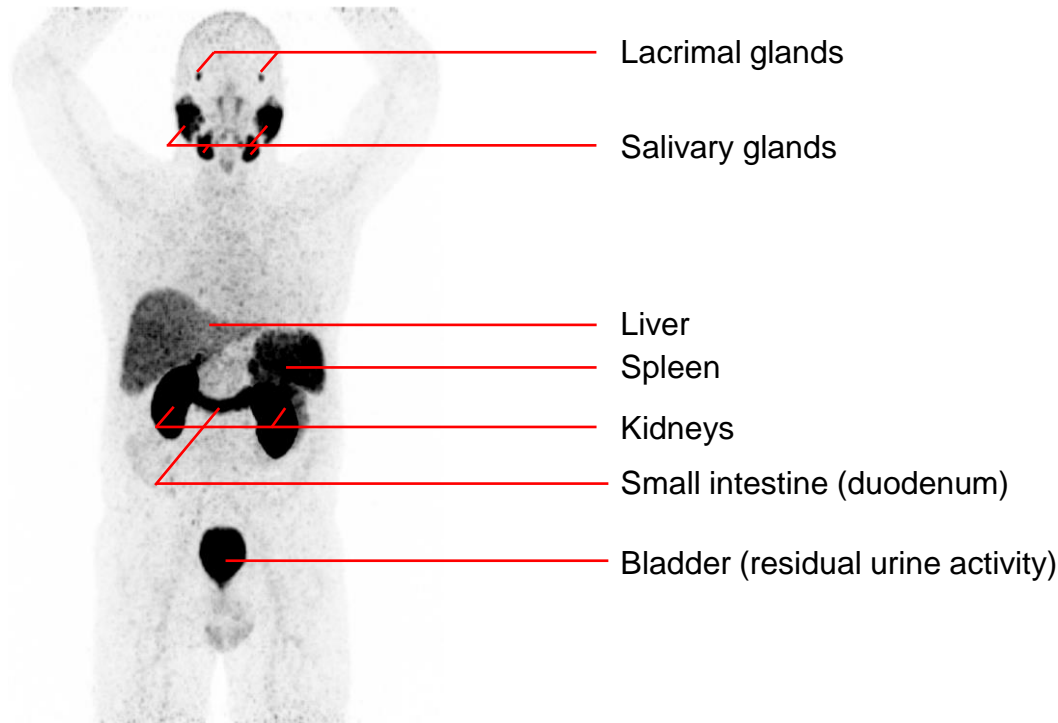
Gallium (^{68}Ga) Gozetotide Case Study Reviews

- In the following slides, different scenarios and comprehensive case study reviews for the interpretation of gallium (^{68}Ga) gozetotide PET scans will be presented, including:
 - Physiological distribution of gallium (^{68}Ga) gozetotide
 - Locametz[®] approved indications
 - Rare locations
 - PSMA expression in other malignant tumors
 - Pitfalls
- Additional information for specific cases are available in the corresponding videos

Physiological Distribution of Gallium (^{68}Ga) Gozetotide

Physiological distribution of gallium (^{68}Ga) gozetotide in a patient after prostatectomy

For specific information on absorbed doses for selected organs and tissues, please refer to the prescribing information.

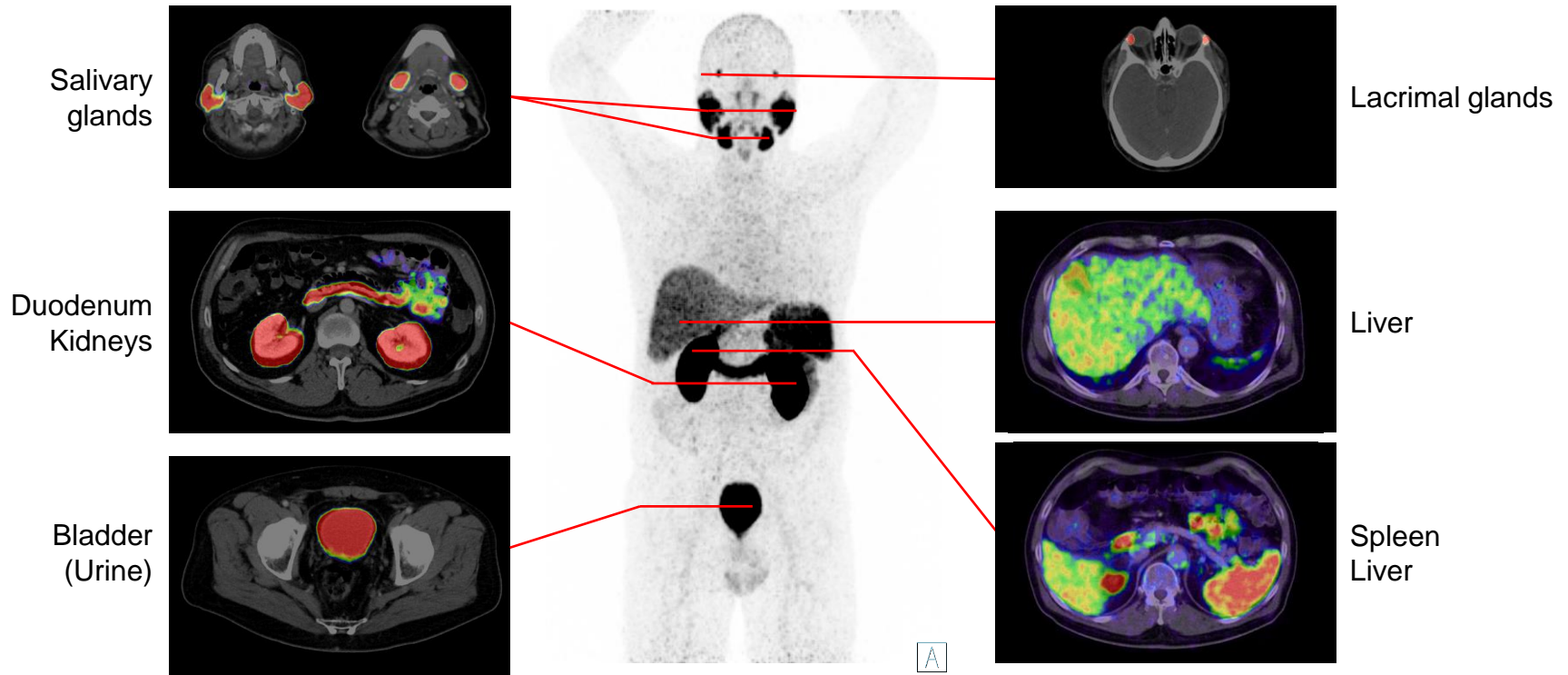


Physiological Distribution of Gallium (^{68}Ga) Gozetotide

▶ CLICK TO PLAY



Physiological distribution of gallium (^{68}Ga) gozetotide in a patient after prostatectomy



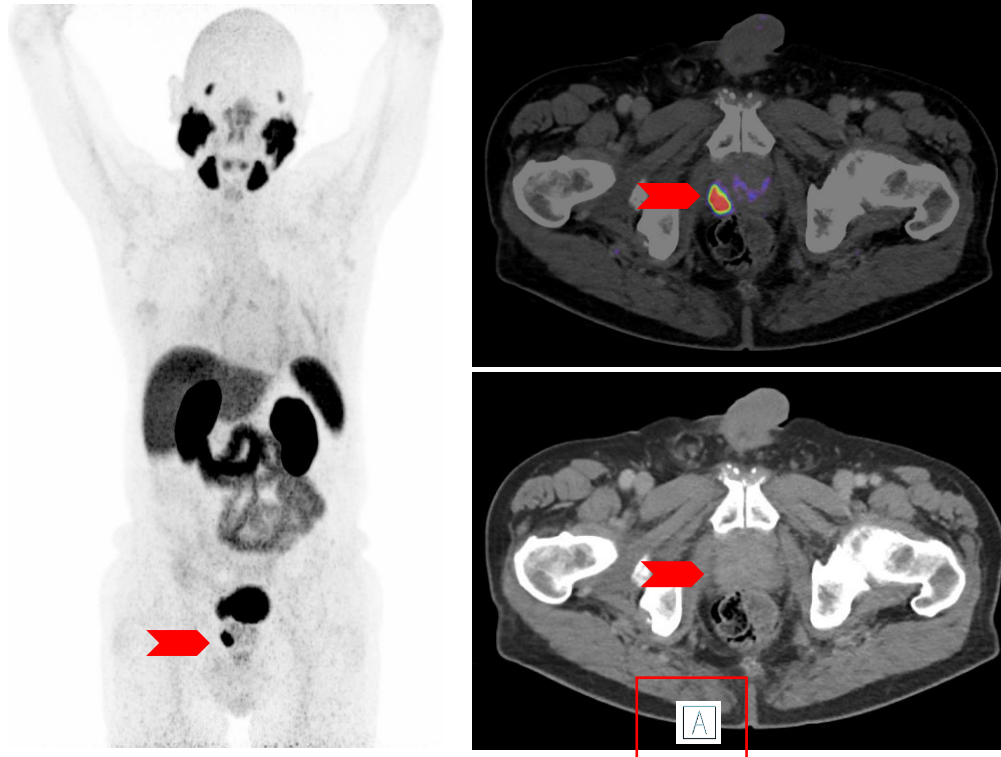
Indications: Current Use Scenarios in the Diagnosis of PCa

- Primary staging of patients with high-risk PCa prior to primary curative therapy



PCa – Unifocal Tumor

Clinical Examples



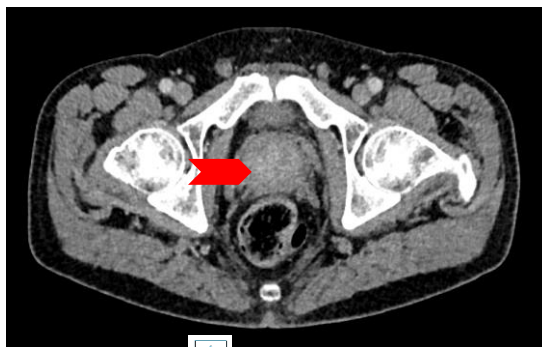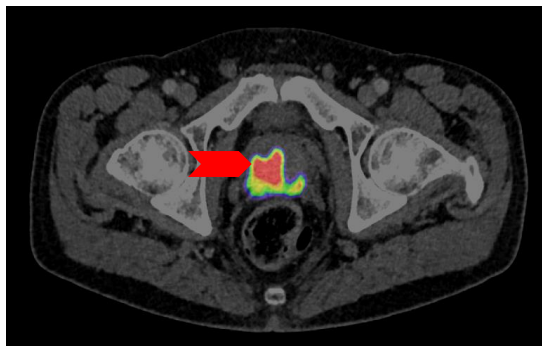
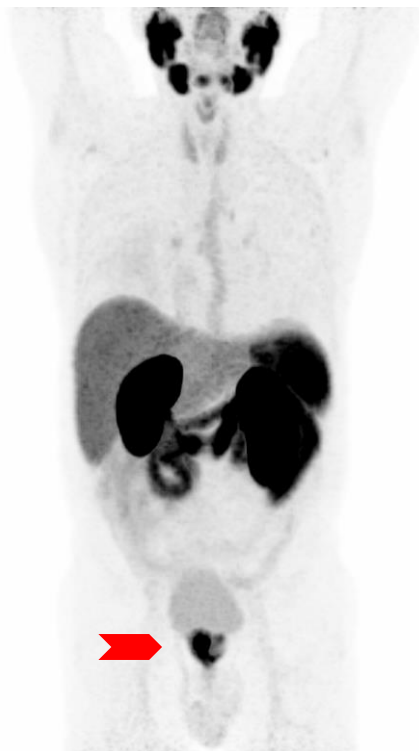- The healthy prostate typically shows a relatively homogeneous gallium (^{68}Ga) gozetotide uptake above the level of the mediastinum and blood pool
- However, the uptake of prostate carcinomas is usually much more intense
- Often, prostate carcinomas with a high uptake also show a correlate on contrast-enhanced CT

Note: the detection of the primary tumor is not indicated for Locametz®



PCa – Multifocal Tumor

Clinical Examples

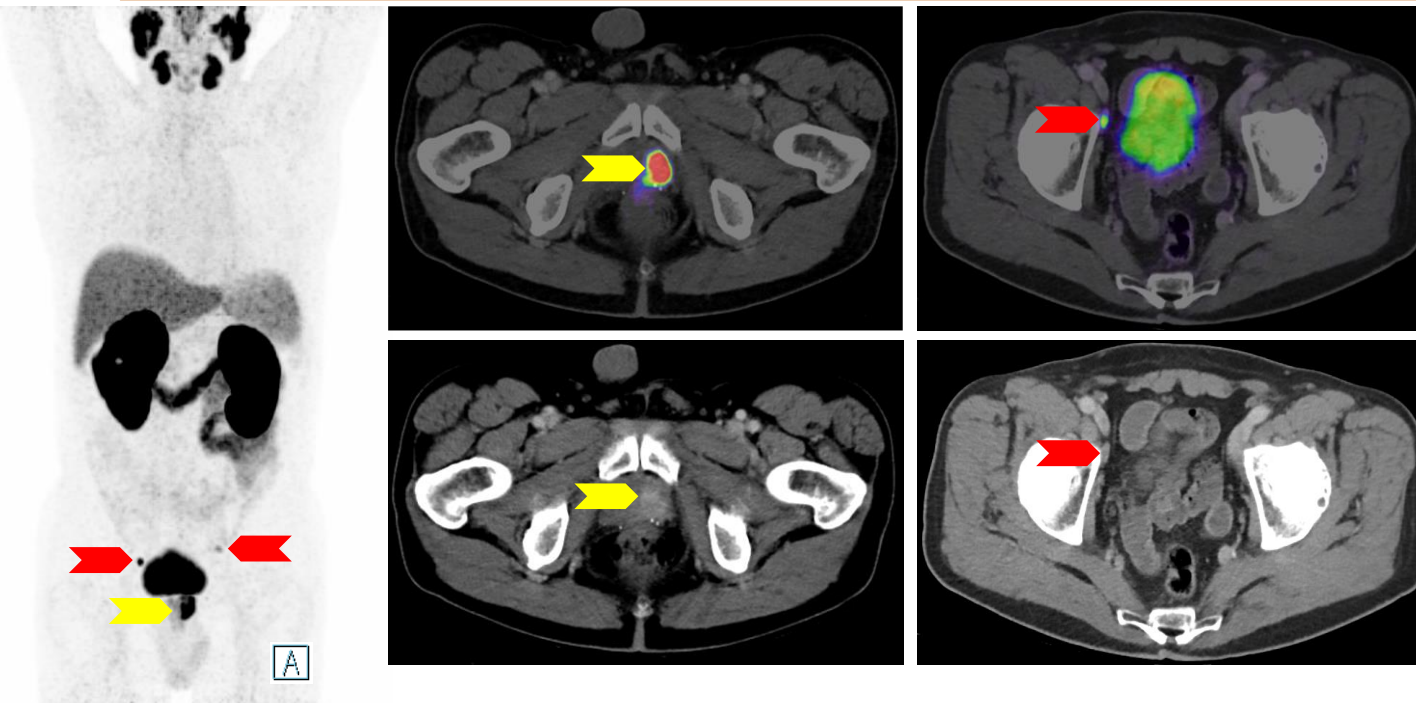


- Multifocal spread patterns are very common in prostate cancer
- The intensity of PSMA expression can vary considerably between individual lesions
- Differentiation from areas with local prostatitis can be difficult, as uptake may be increased in these areas

Note: the detection of the primary tumor is not indicated for Locametz®

PCa - Multifocal Tumor With Pelvic Lymph Node Metastases

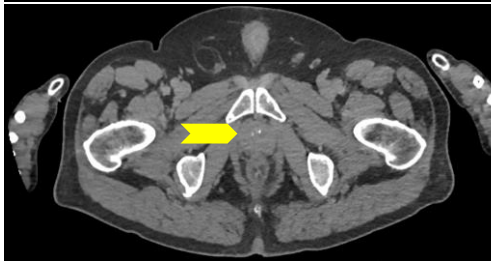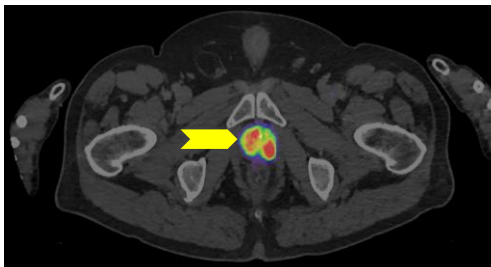
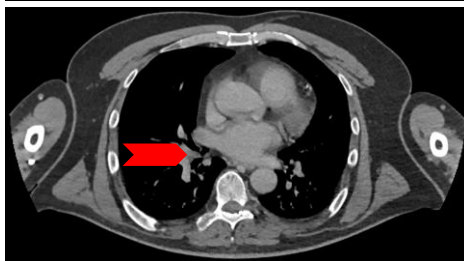
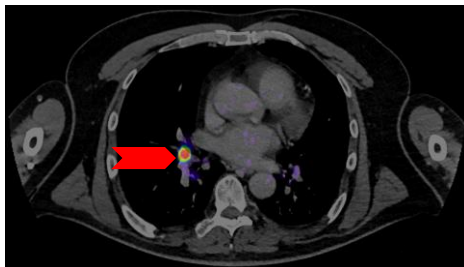
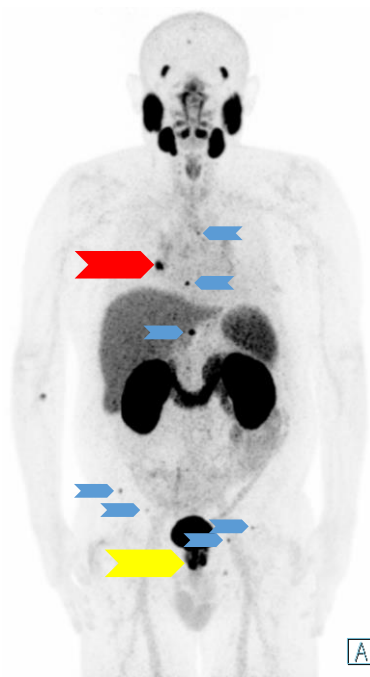
Clinical Examples



- High-risk PCa prior to any therapy
 - Gleason: 9 (4+5)
 - Initial PSA: 53 ng/mL
- Yellow arrow: multifocal prostate cancer
- Red arrow: lymph node metastasis

PCa - Multifocal Tumor With Distant Metastases

Clinical Examples



- High-risk PCa
 - Gleason: 9
 - Initial PSA: 29 ng/ml
 - Initial conventional staging (CT) without pathological findings
- Yellow arrow: multifocal prostate cancer
- Red arrow: lymph node metastasis
- Blue arrow: bone metastases

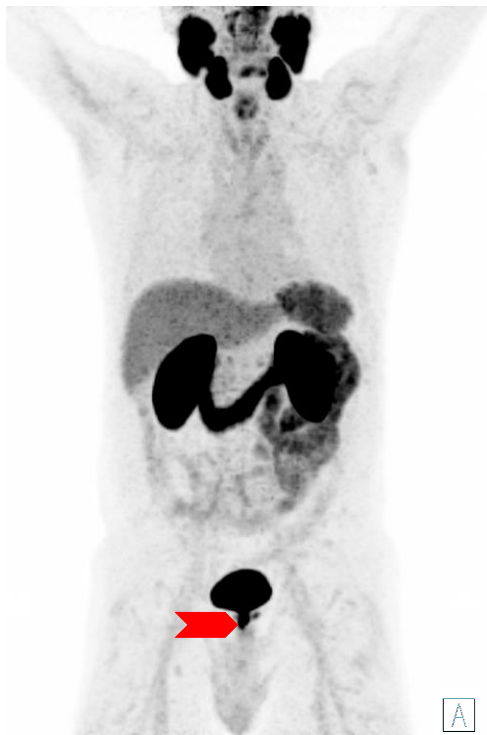Indications: Current Use Scenarios in the Diagnosis of PCa

- Suspected PCa recurrence in patients with increasing levels of serum prostate-specific antigen (PSA) after primary curative therapy

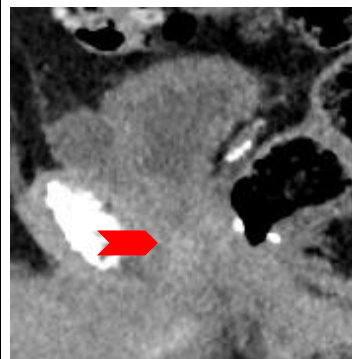
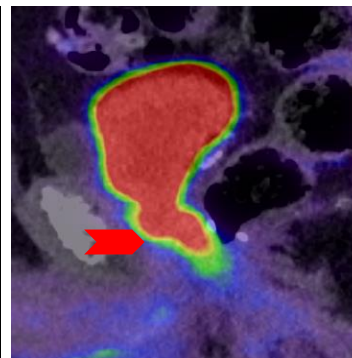
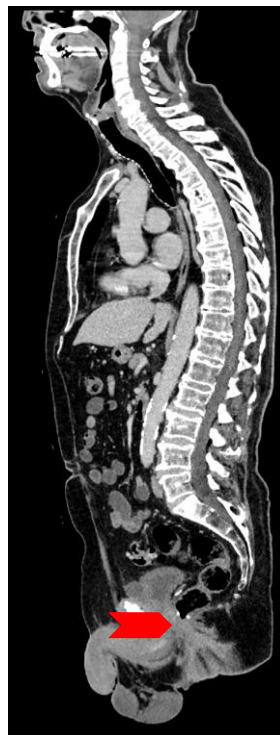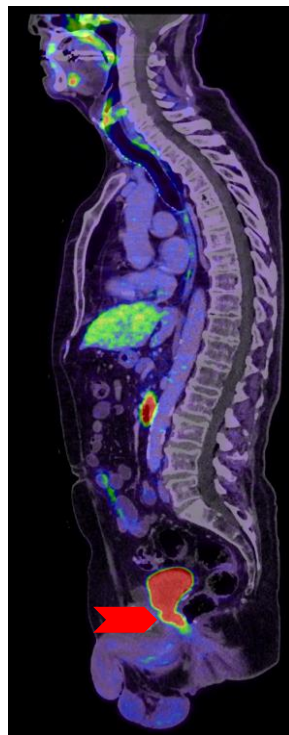


PCa - Local Recurrence

Clinical Examples



A

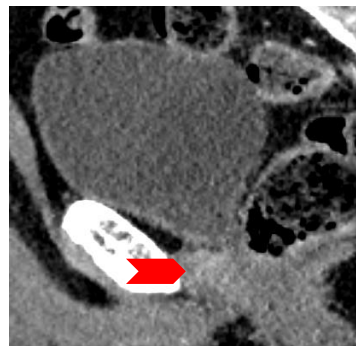
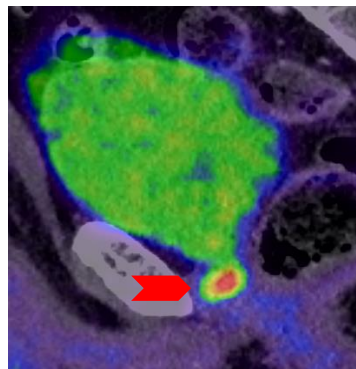
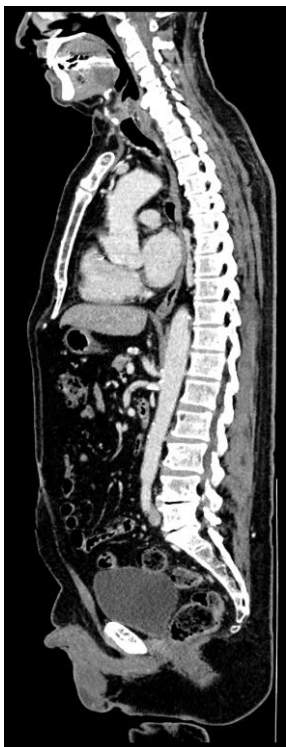
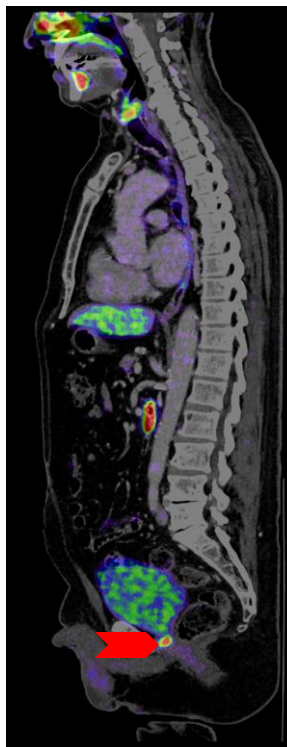
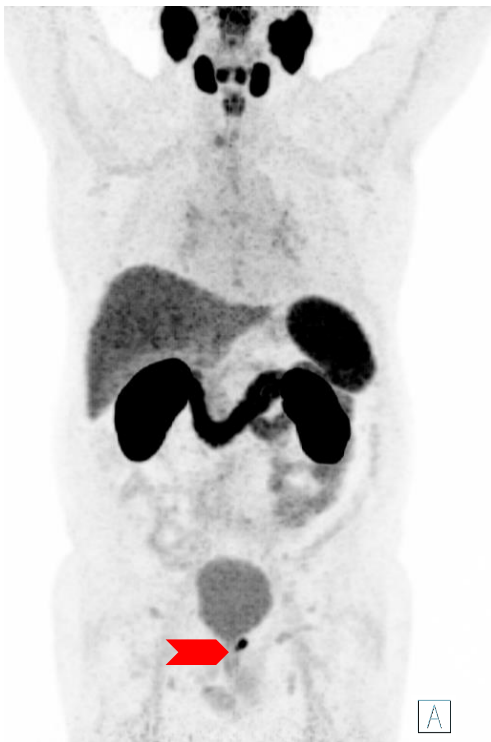
- Case of a PET/CT without prior injection of furosemide
- Local recurrence of prostate cancer is indistinguishable from the bladder due to tracer excretion



PCa - Local Recurrence

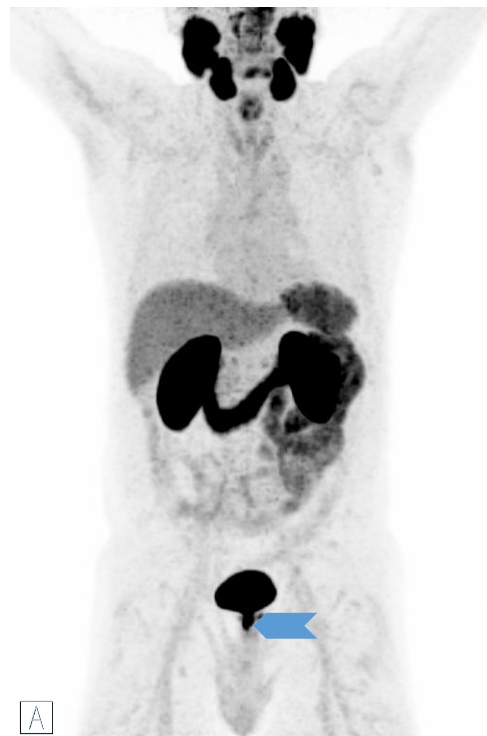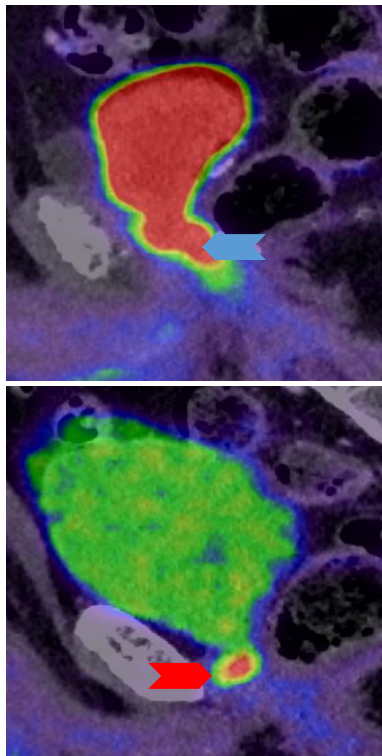
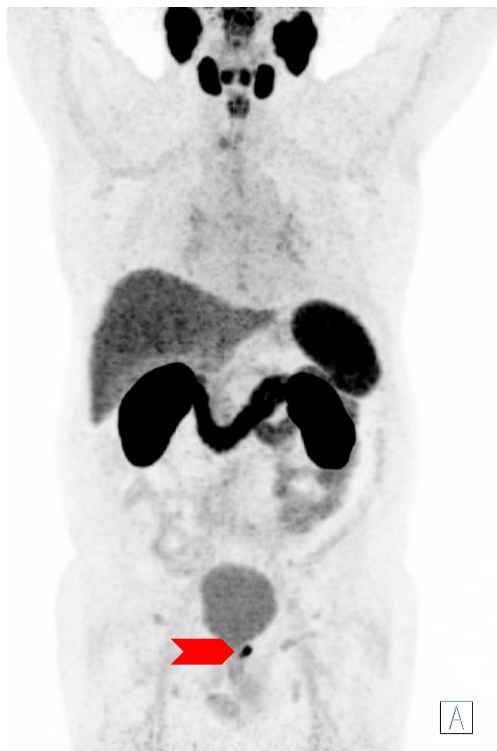Clinical Examples



- Case of a PET/CT with prior injection of furosemide
- Accelerated tracer excretion results in dilution of radioactivity in the bladder (see MIP)
- The local recurrence now distinguishes itself much more clearly from the urinary bladder

PCa - Local Recurrence

Clinical Examples

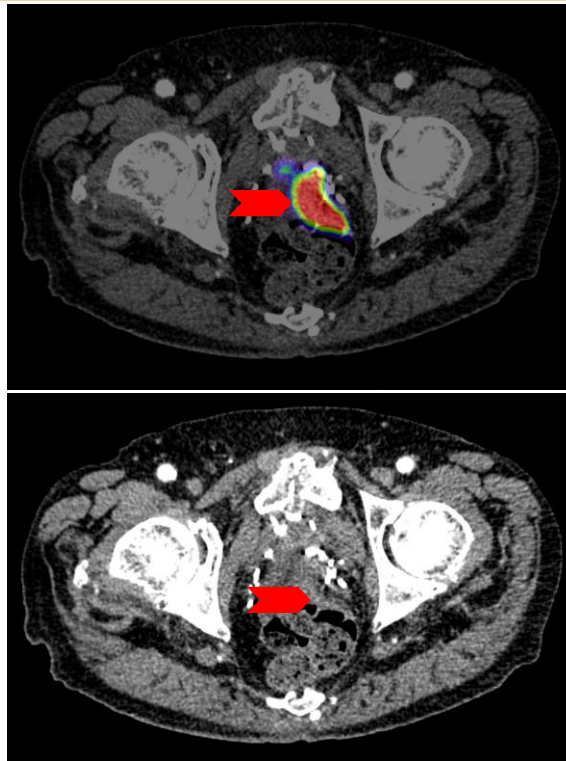
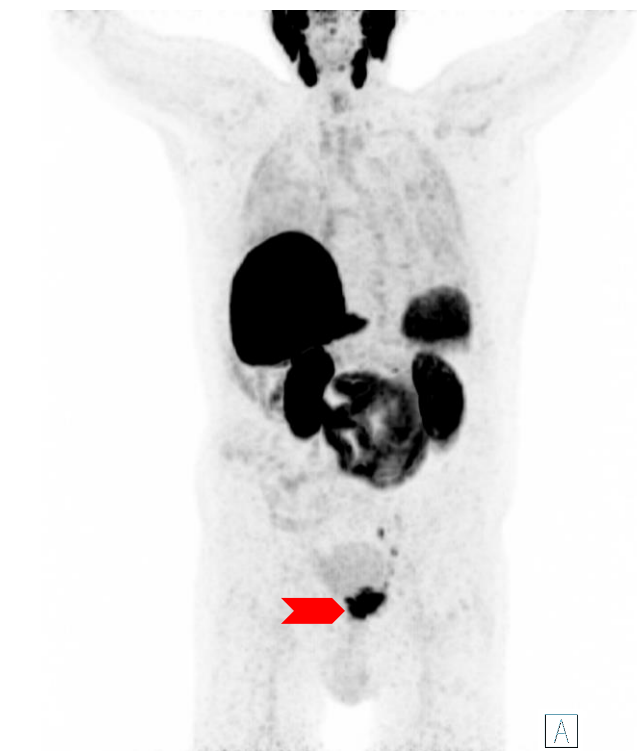


- Direct comparison of the presentation of local recurrences with and without the use of furosemide
 - Consider the injection of furosemide

PCa - Local Recurrence (Colon Infiltration)

Clinical Examples

▶ CLICK TO PLAY

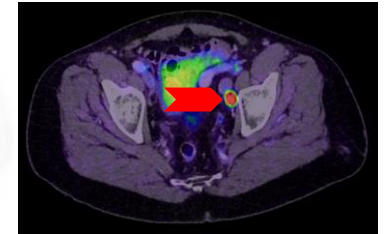
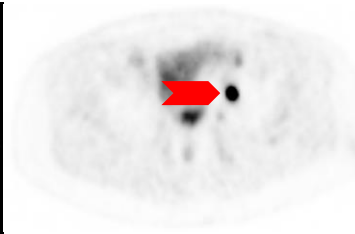
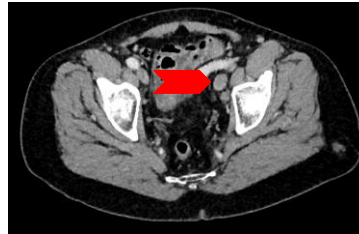
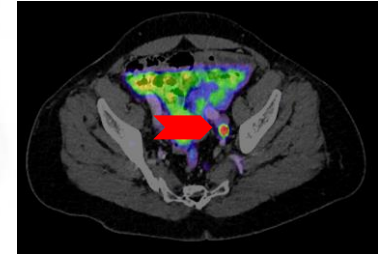
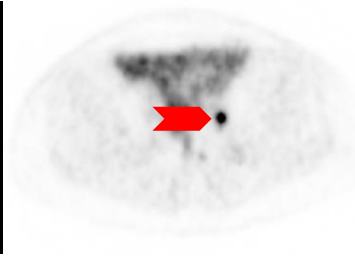
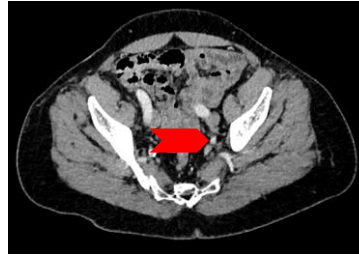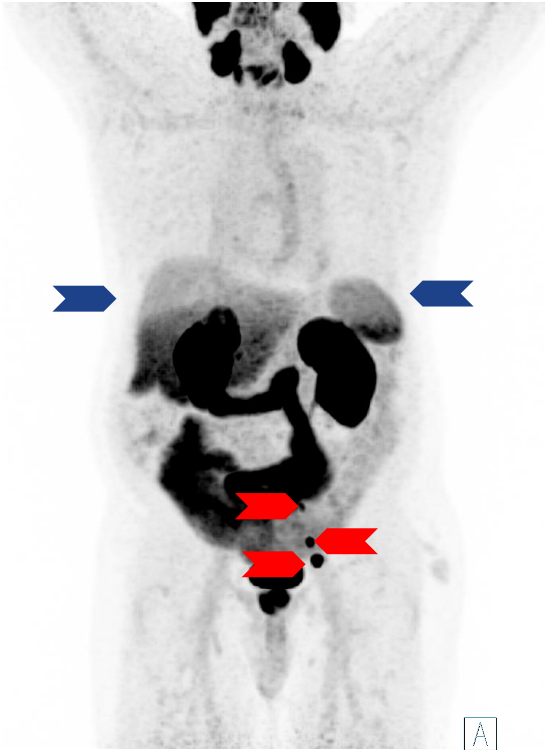


- The use of gallium (^{68}Ga) gozetotide in this example reveals a complicated case of local recurrence with infiltration of another organ, which would have been very difficult to diagnose by conventional staging



Local Lymph Nodes (Iliac)

Clinical Examples

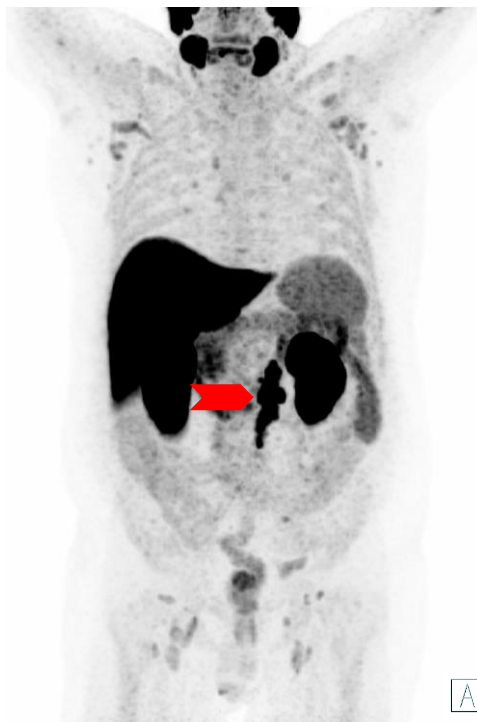

- Iliac lymph nodes are one of the most common sites for prostate cancer metastasis
- However, these lymph node metastases are often not pathologically enlarged
- Gallium (^{68}Ga) gozetotide helps tremendously with staging
- The heterogenous uptake in liver and spleen (blue arrows) is due to breathing artifacts

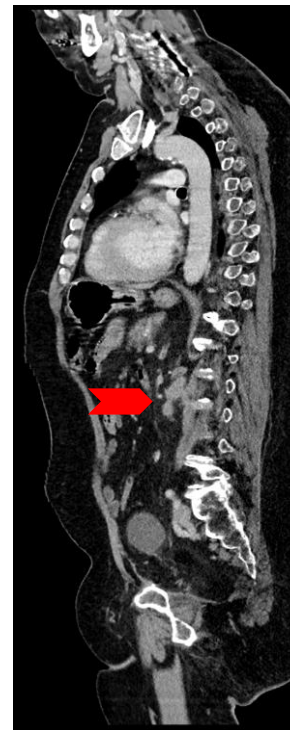
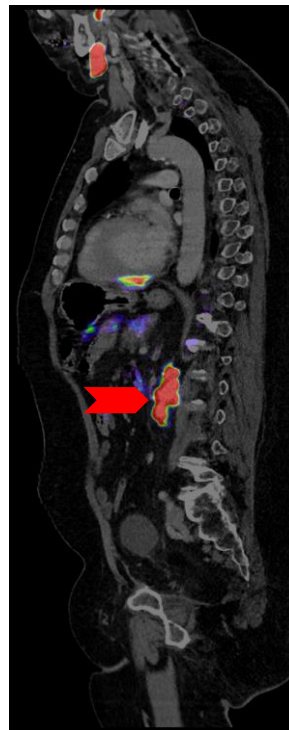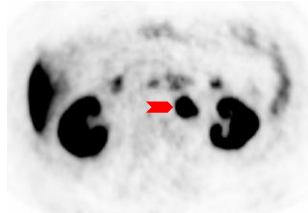
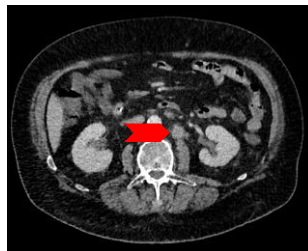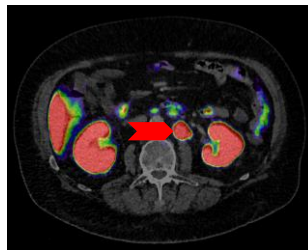Distant Lymph Nodes (Retroperitoneal)

Clinical Examples

▶ CLICK TO PLAY



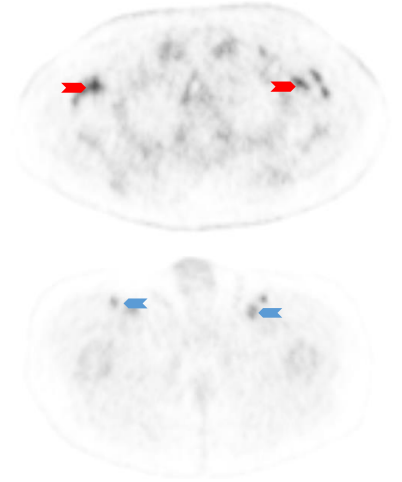
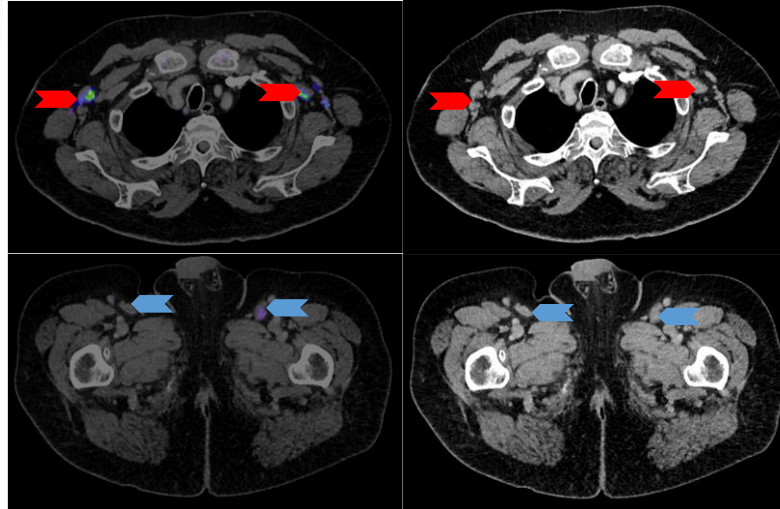
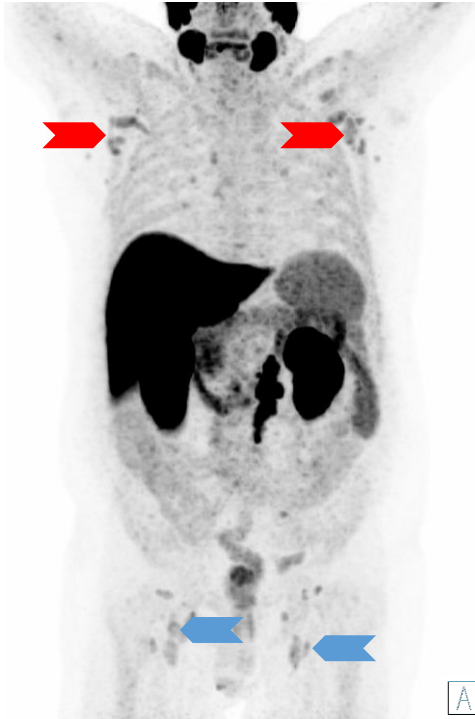A



- Retroperitoneal lymph nodes may also be affected
- These must not be confused with ganglia of the sympathetic trunk

Distant Lymph Nodes (Retroperitoneal)

Clinical Examples



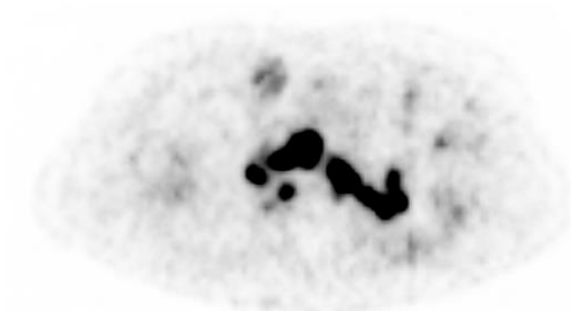
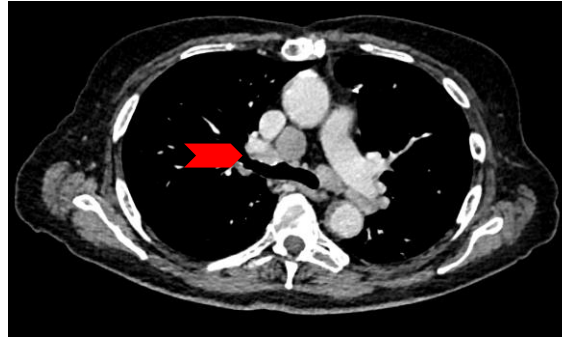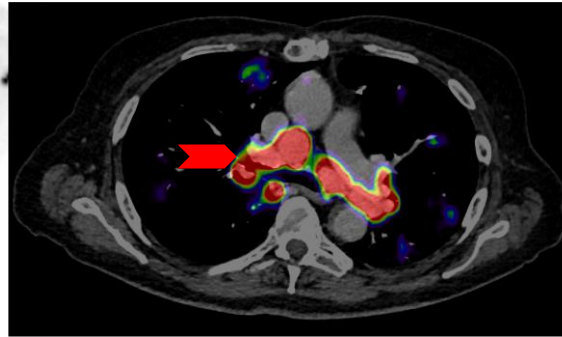
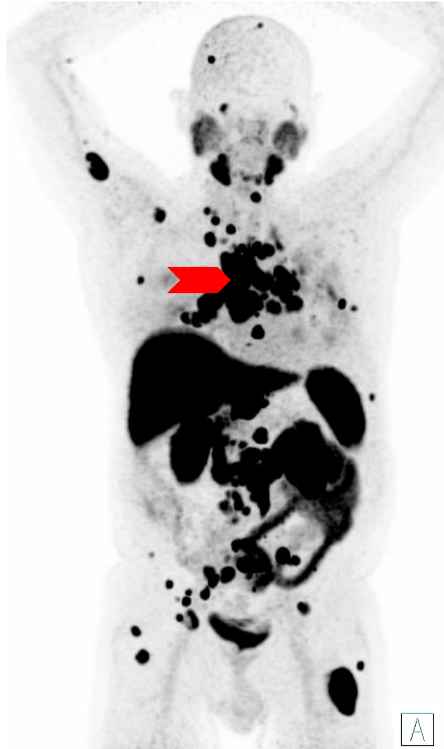- Symmetrical gallium (^{68}Ga) gozetotide uptake (level 1) in axillary, inguinal, and mediastinal lymph nodes
 - PROMISE criteria: low probability of malignancy, follow-up suggested



Distant Lymph Nodes (Mediastinal)

Clinical Examples

▶ CLICK TO PLAY



- Thoracic lymph node metastases are rather rare
- These usually occur at an advanced stage in the presence of many other metastases
- Additional causes for isolated gallium (^{68}Ga) gozetotide uptake only in the mediastinal must therefore be questioned (for example, sarcoidosis or second malignancy)

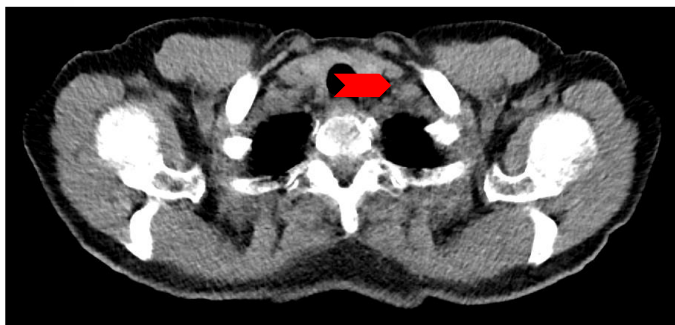
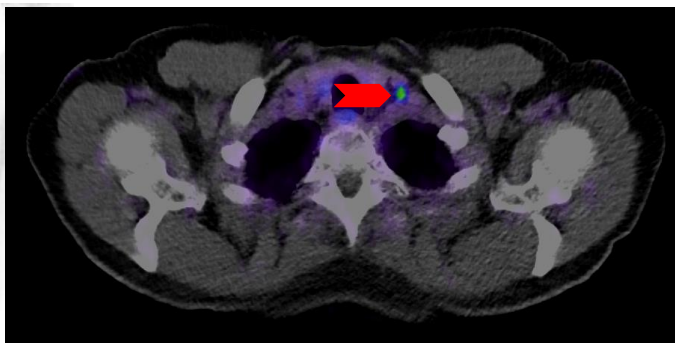
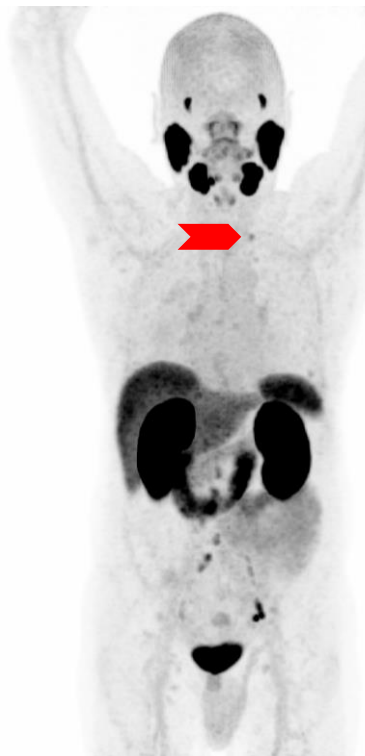
A

Distant Lymph Nodes (Supraclavicular – Virchow's Node)

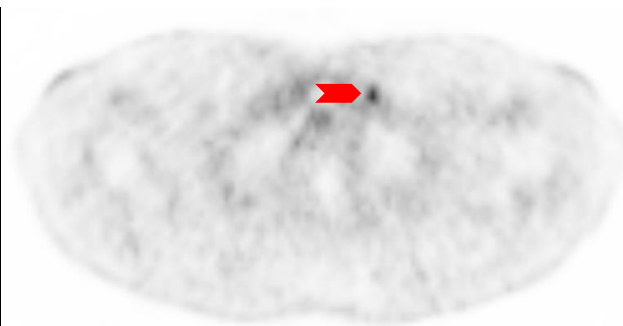
▶ CLICK TO PLAY



Clinical Examples



A

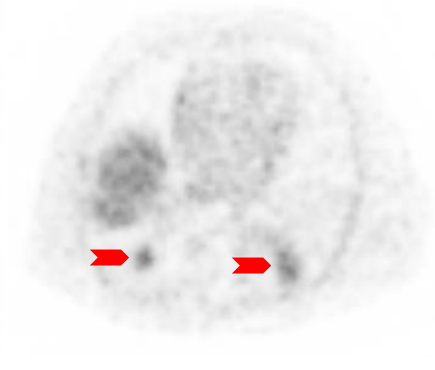
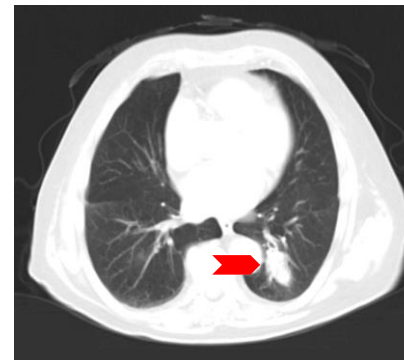
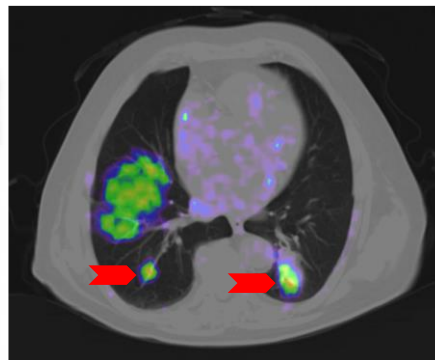
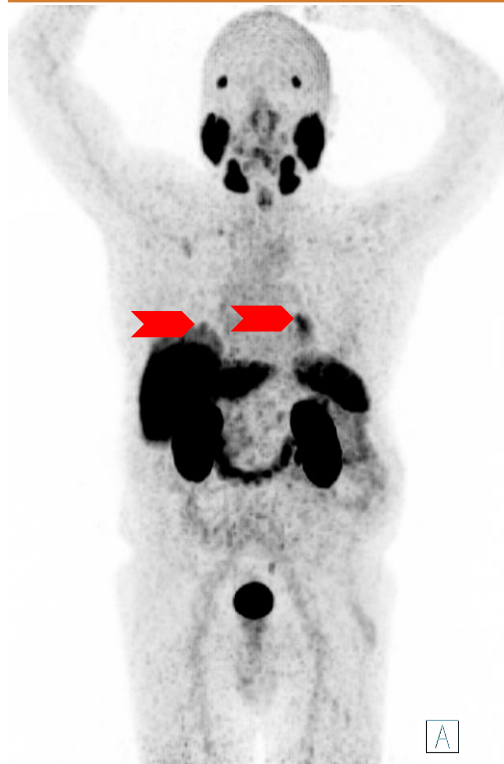

- Side note: interestingly, gallium (^{68}Ga) gozetotide uptake also repeatedly unmasks left supraclavicular lymph node metastases (so-called Virchow's lymph nodes), which would often remain hidden on conventional CT due to the non-intuitive localization



Pulmonary Metastases

Clinical Examples

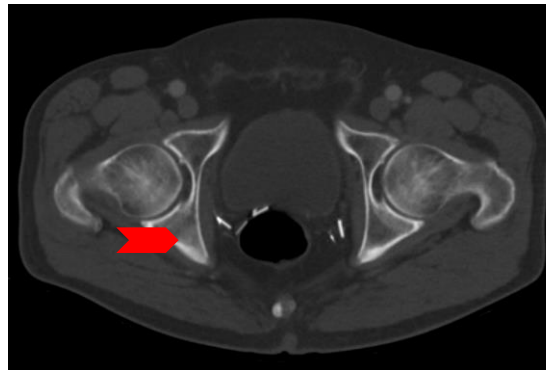
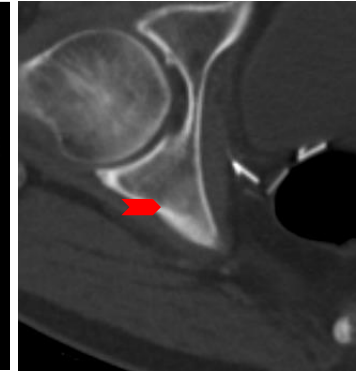
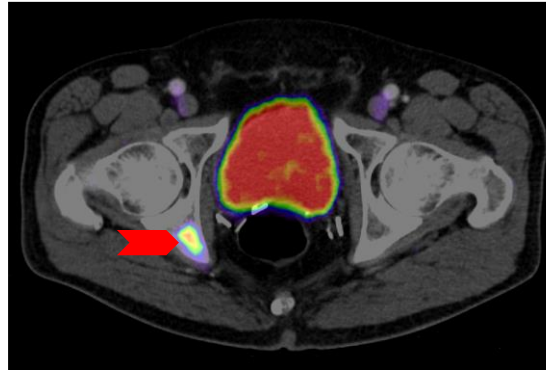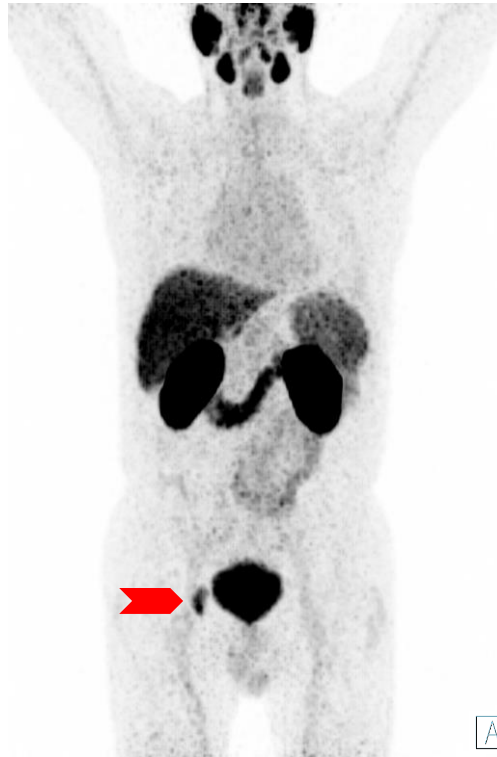


- Lung metastases in prostate cancer are rare but cannot be ruled out
- A detailed study of the individual case is important in weighing up the diagnosis of pulmonary metastases against a second PSMA-positive malignancy
- Side note: breathing artifacts can complicate the diagnosis. Use all available image series for better assignment of tracer uptake

Solitary Bone Metastases

Clinical Examples

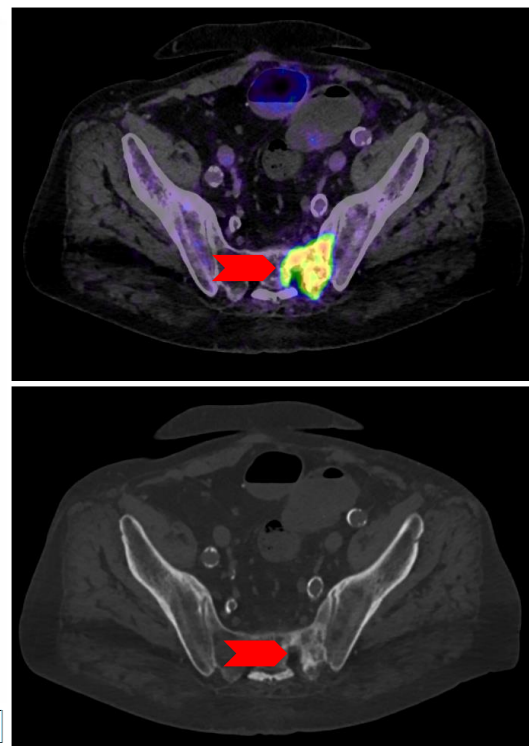
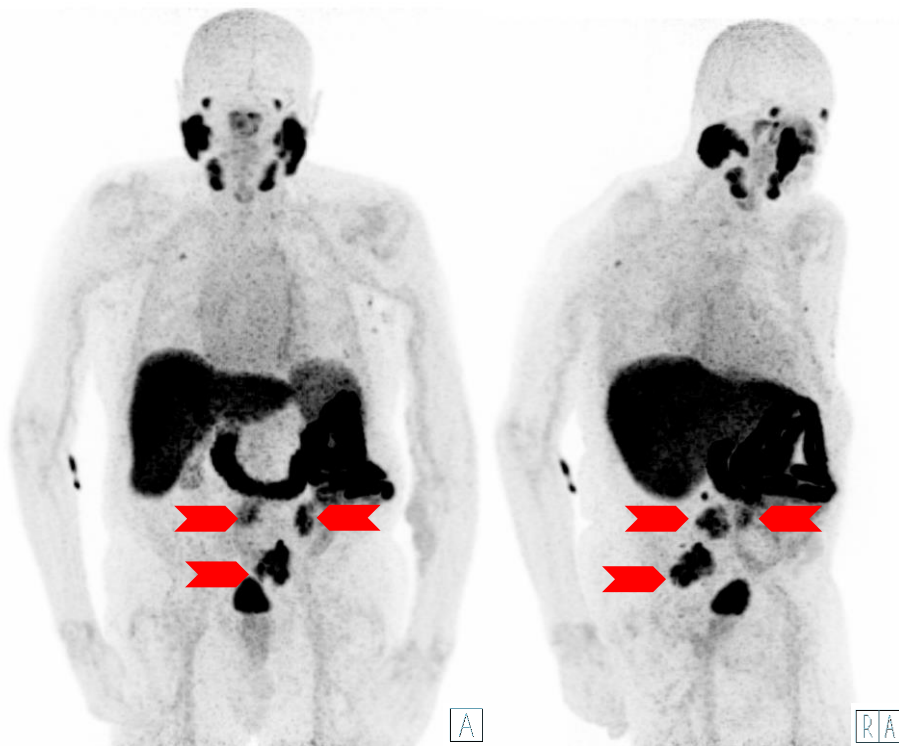
▶ CLICK TO PLAY



- Typically, bone metastases from prostate cancer are osteoblastic in nature and therefore, are also easily detected on CT
- However, usage of gallium (^{68}Ga) gozetotide increases the sensitivity of detection compared to CT and bone scintigraphy

Polytopic Bone Metastasis

Clinical Examples



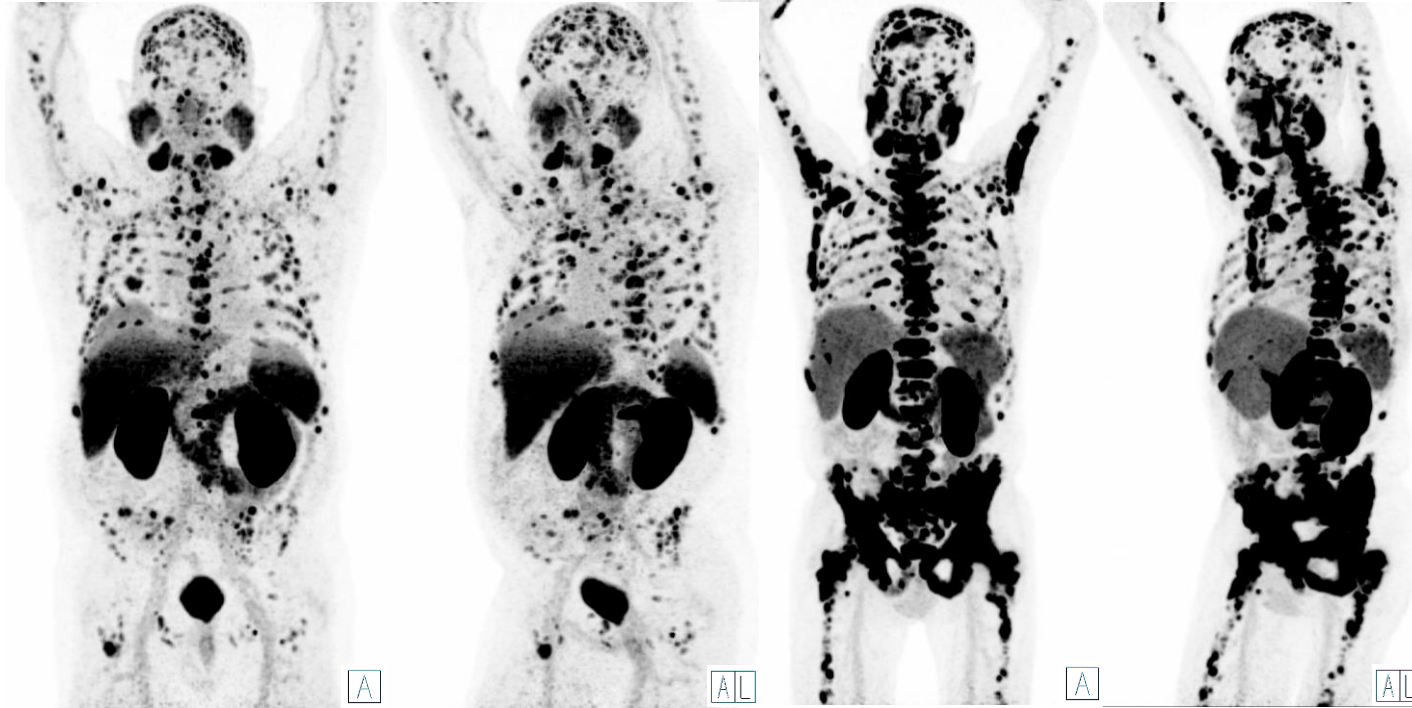
- In this case, multiple, osteoblastic bone metastases with intense PSMA expression are seen

Disseminated Bone Metastases and Diffuse Bone Marrow Infiltration

▶ CLICK TO PLAY



Clinical Examples



- Disseminated bone metastases should not be confused with co-occurring diffuse bone marrow infiltration

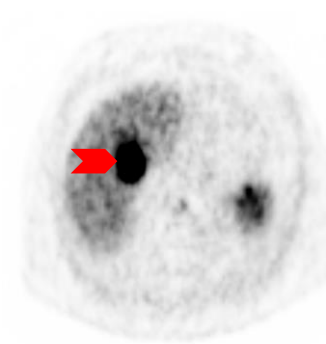
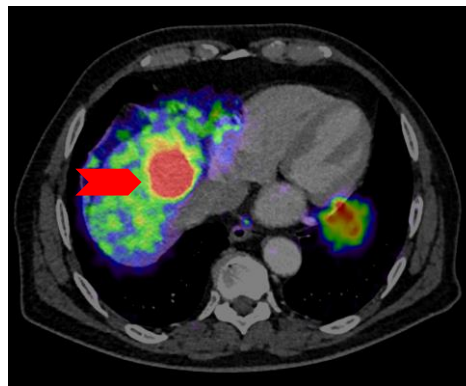
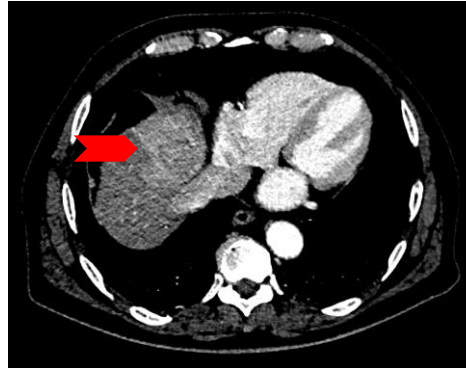
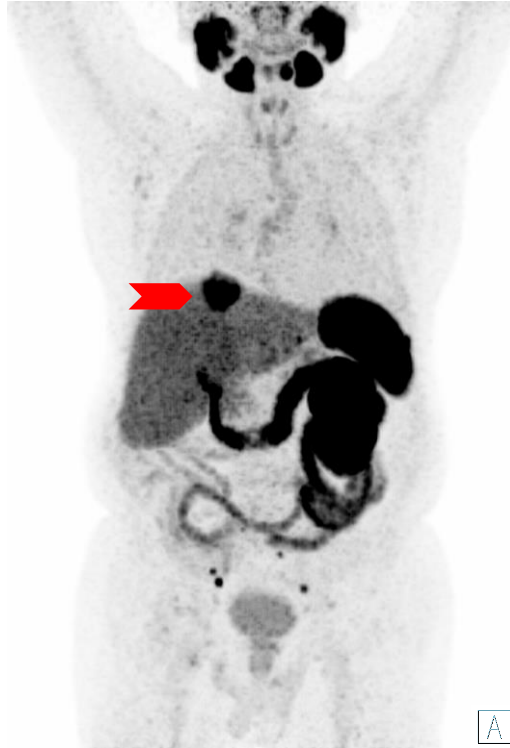Disseminated bone metastases

Diffuse bone marrow infiltration

Single Hepatic Metastasis

Clinical Examples

▶ CLICK TO PLAY



Additional lymph node metastases in the pelvis

- Liver metastases usually occur later in the course of PCa, especially in high-risk patients
- However, since HCCs can also have gallium (^{68}Ga) gozetotide uptake, clinical classification or biopsy confirmation is important

Indications: Current Use Scenarios in the Diagnosis of PCa

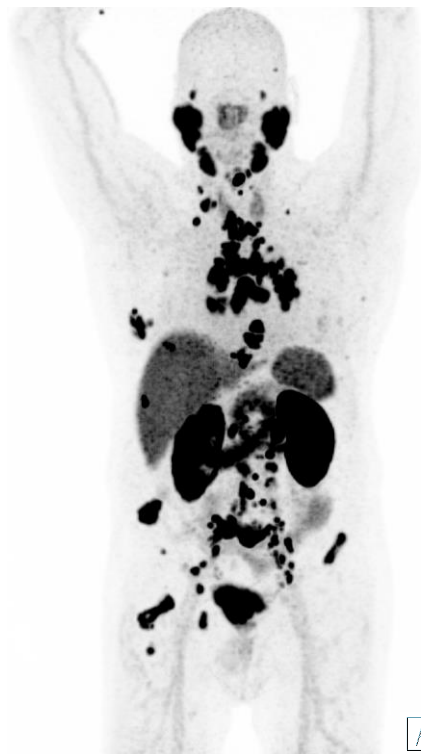- Identification of patients with PSMA-positive progressive metastatic castration-resistant prostate cancer (mCRPC) for whom PSMA-targeted therapy is indicated

Case for the Identification of a Patient for Whom PSMA-Targeted Therapy Is Indicated

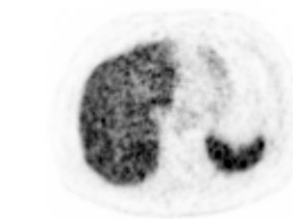
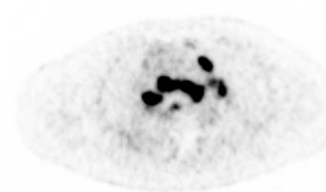
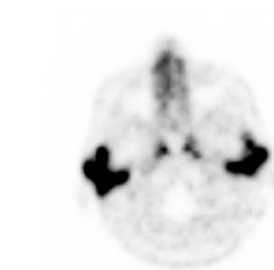
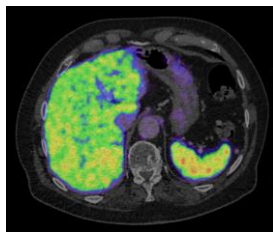
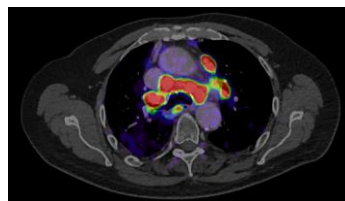
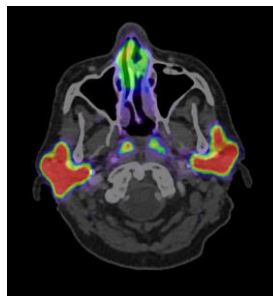
▶ CLICK TO PLAY



Clinical Examples



A

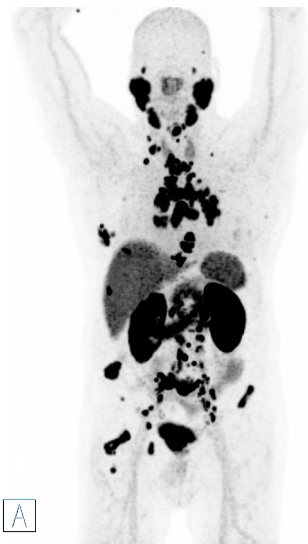

- Feasibility of PSMA radioligand therapy should be a visual assessment:
 - At least one lesion with gallium (^{68}Ga) gozetotide uptake higher than liver
 - Majority of tumor lesions should have a gallium (^{68}Ga) gozetotide uptake above the liver (level 2), or more
 - All tumor lesions show an uptake at least above the liver level
- A good RLT therapy candidate

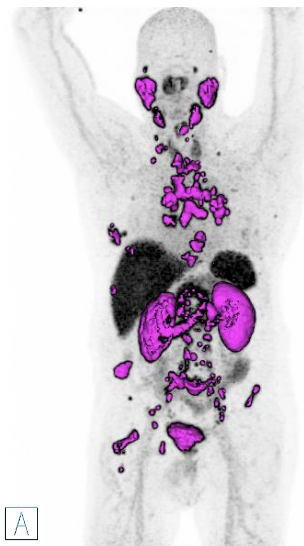
Case for the Identification of a Patient for Whom PSMA-Targeted Therapy Is Indicated

Clinical Examples

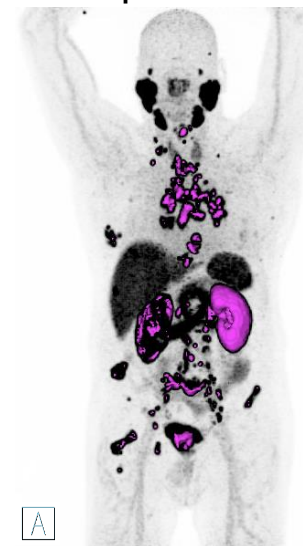
MIP showing the gross tumor distribution and gallium (^{68}Ga) gozetotide uptake



MIP showing lesions and physiological gallium (^{68}Ga) gozetotide uptake above liver level



MIP showing lesions and physiological gallium (^{68}Ga) gozetotide uptake above parotid level

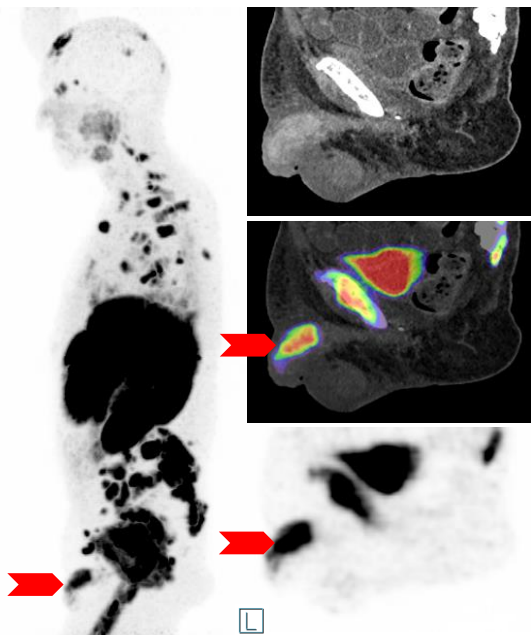


All highlighted tumor lesions have a good chance to respond to PSMA-targeted RLT

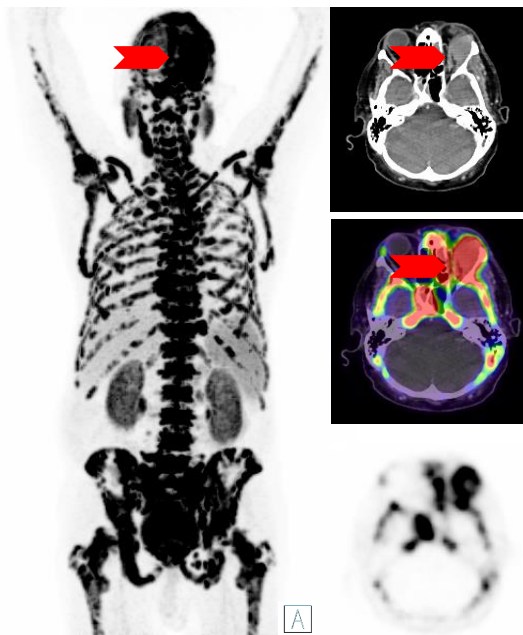
Rare Locations

Rare Locations

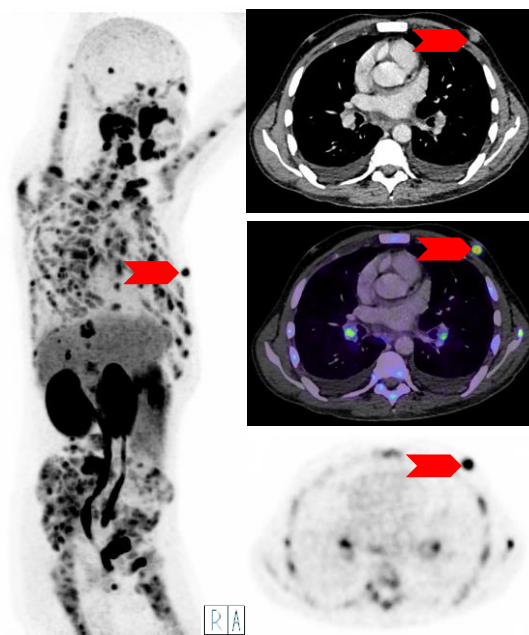
Clinical Examples



Penis metastasis



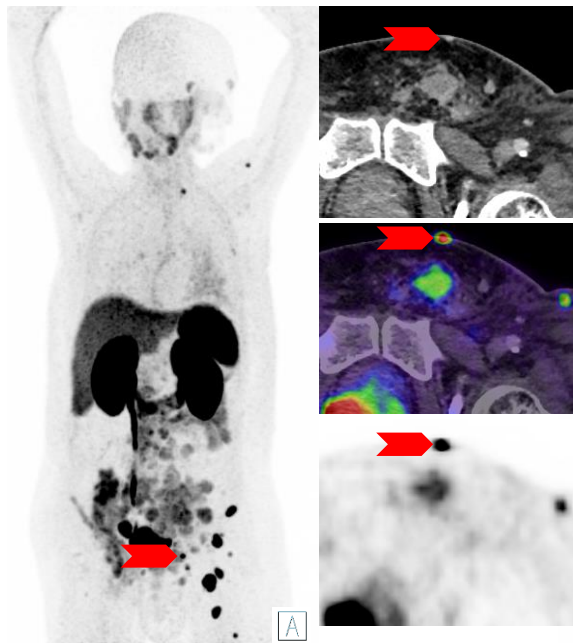
**Metastasis in the left orbita
(eyeball is pressed down)**



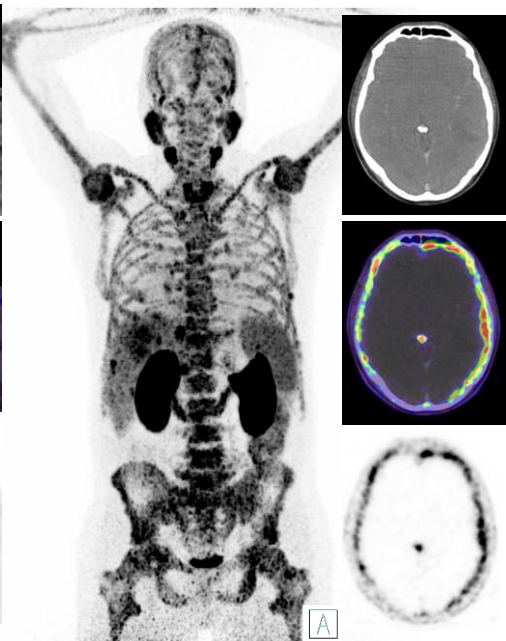
**Metastasis of
the left mamma**

Rare Locations

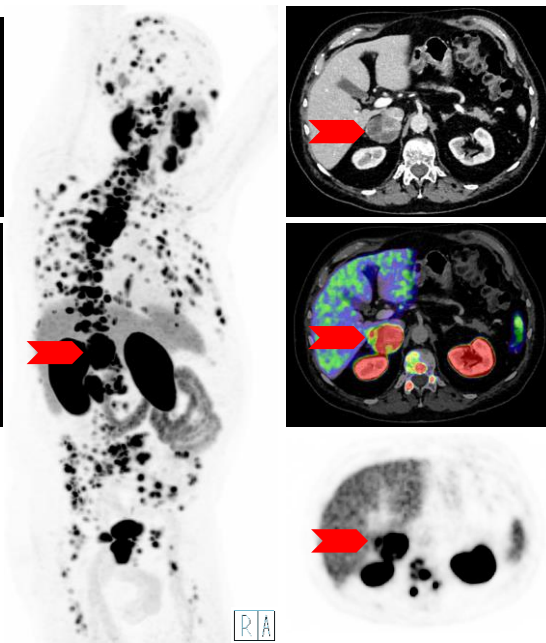
Clinical Examples



Metastasis of the skin



**Brain ventricular
metastasis**

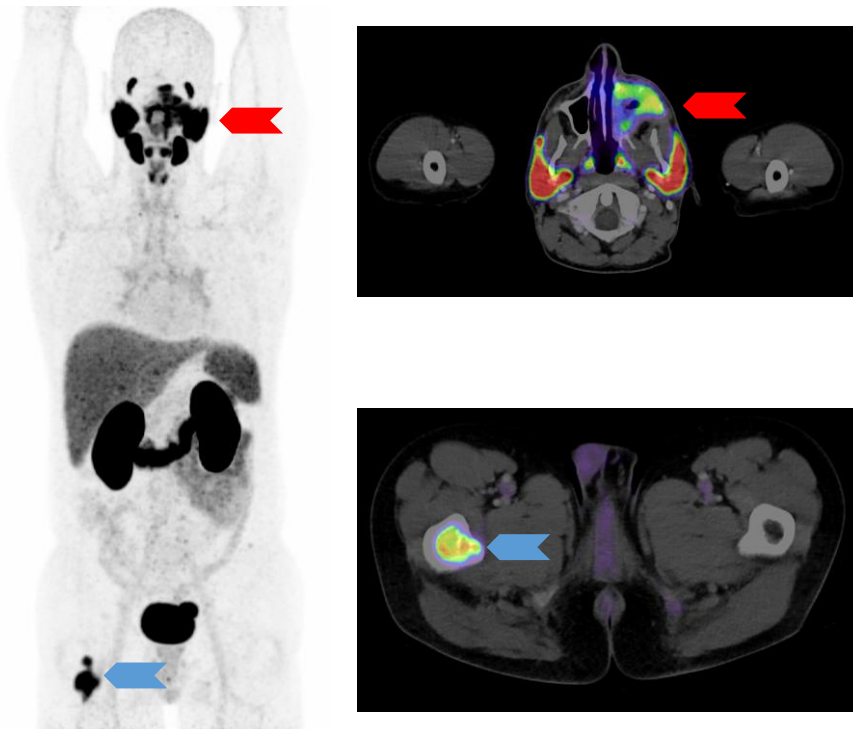


**Metastasis of the
right adrenal gland**

PSMA Expression in Other Malignant Tumors

PSMA Expression in Other Malignant Tumors

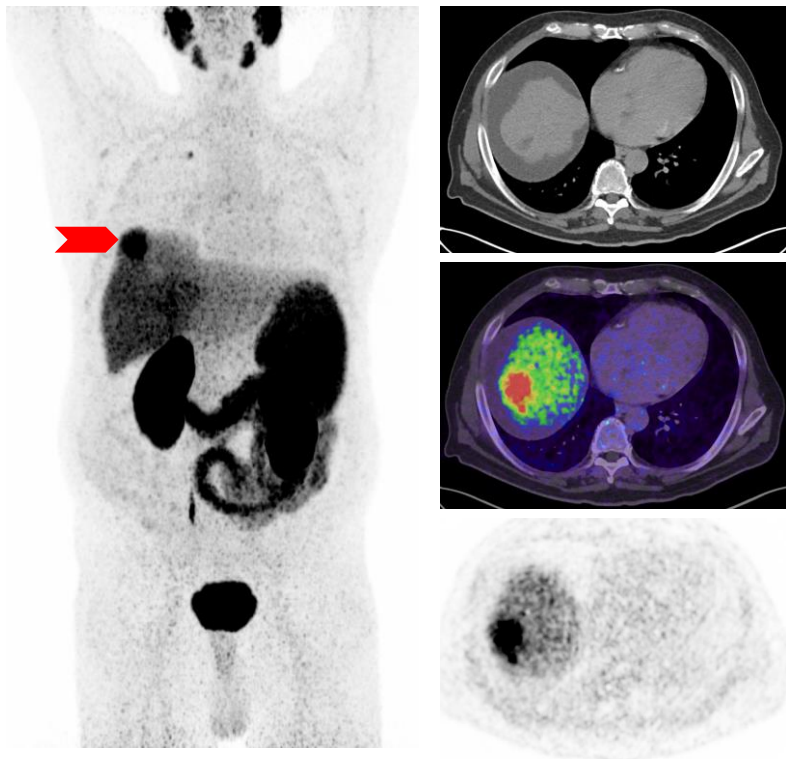
Adenoid Cystic Carcinoma (ACC) and Salivary Duct Carcinoma



- Concordant to physiological PSMA expression in the salivary glands, salivary gland carcinomas (and their metastases) may also show increased PSMA expression
- Individual windowing, to distinguish physiological uptake from possible pathological uptake of the salivary glands, is necessary in every examination

PSMA Expression in Other Malignant Tumors

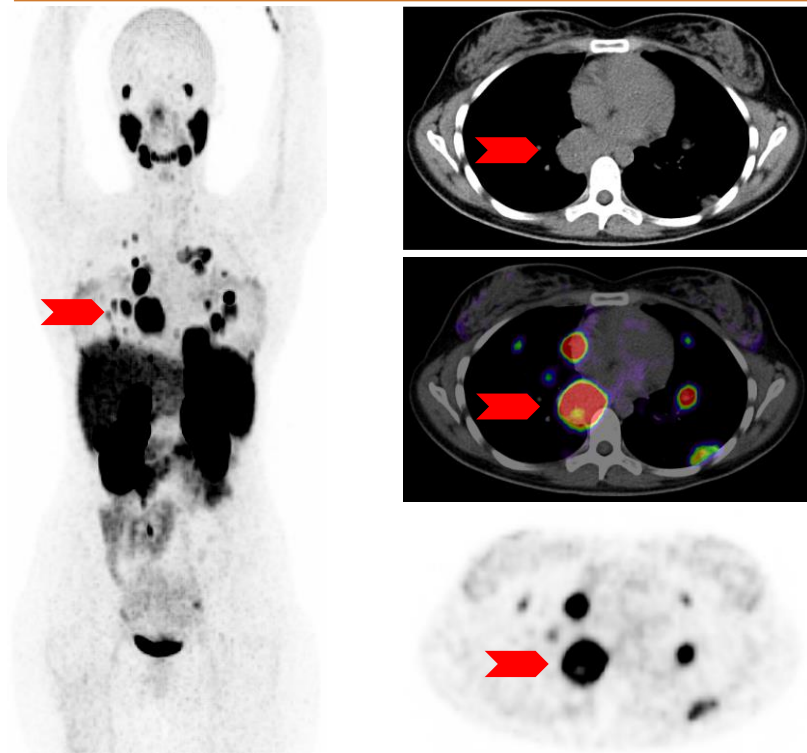
Hepatocellular Carcinoma (HCC)



- Most HCCs show increased PSMA expression and can be detected by PSMA PET/CT scans
- Caveat: due to the tendency of prostate cancer to also spread to the liver, an accurate history and clinical assessment (ISUP grade group, PSA, other organ metastases, clinical history) is important in differentiating between primary liver lesions and metastases
 - The tendency of liver metastases to de-differentiate makes this distinction even more difficult based on PSMA uptake alone

PSMA Expression in Other Malignant Tumors

Sarcoma etc.



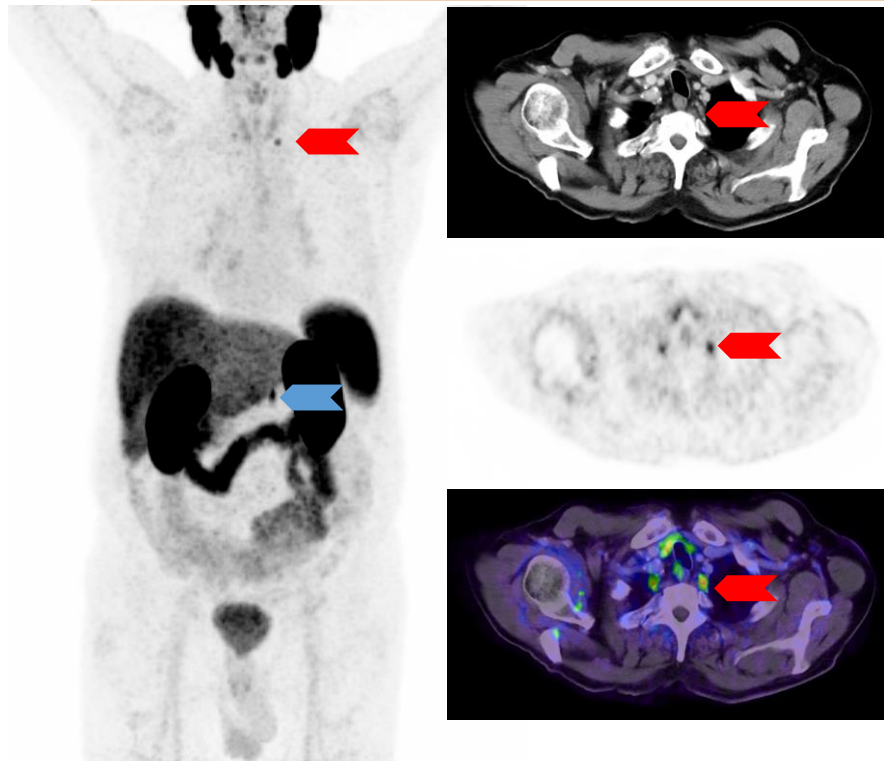
- Probably due to its involvement in tumor-associated neovasculature, PSMA ligand uptake is also described in other tumors such as sarcomas
- Ultimately, any other tumor type could also show a (rather non-specific) increased PSMA ligand uptake than healthy tissue due to increased vascularization
 - Considering individual tracer accumulations in the overall context of the case is therefore extremely important

Pitfalls

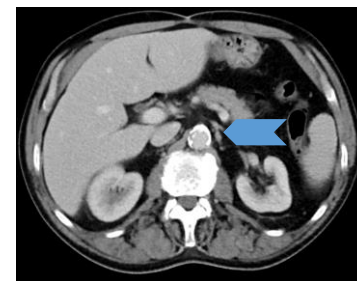
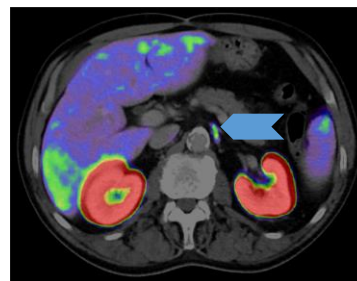


Pitfalls

Ganglia of the Sympathetic Trunk



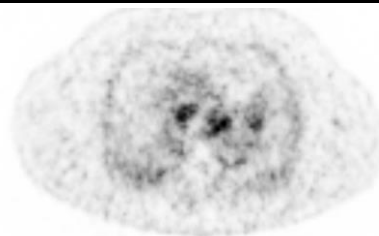
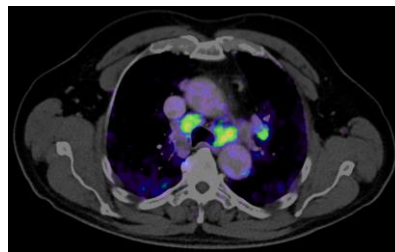
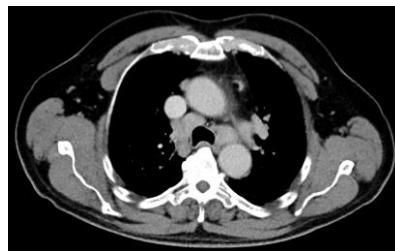
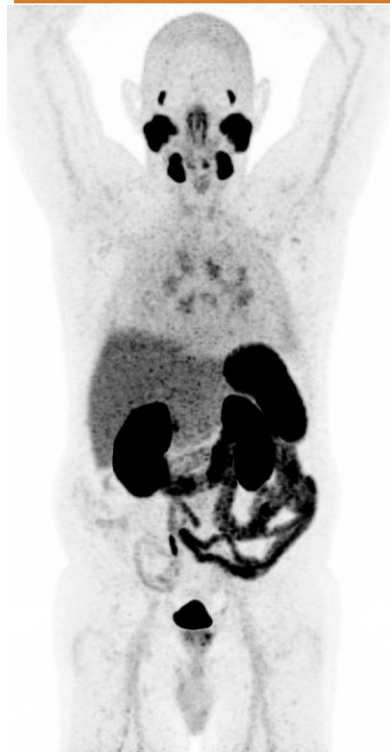- Gallium (^{68}Ga) gozetotide uptake in ganglia is very common in healthy and/or reactive ganglia without involvement of prostate cancer
 - It can be difficult to distinguish these from lymph node metastases
- Useful criteria in the distinction of ganglia to lymph node metastases include:
 1. Symmetrical occurrence
 2. Specific anatomic landmarks (cervical, celiac, sacral)
 3. Band-shaped or teardrop configuration



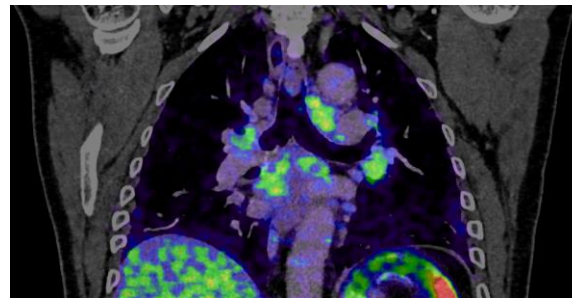


Pitfalls

Sarcoidosis



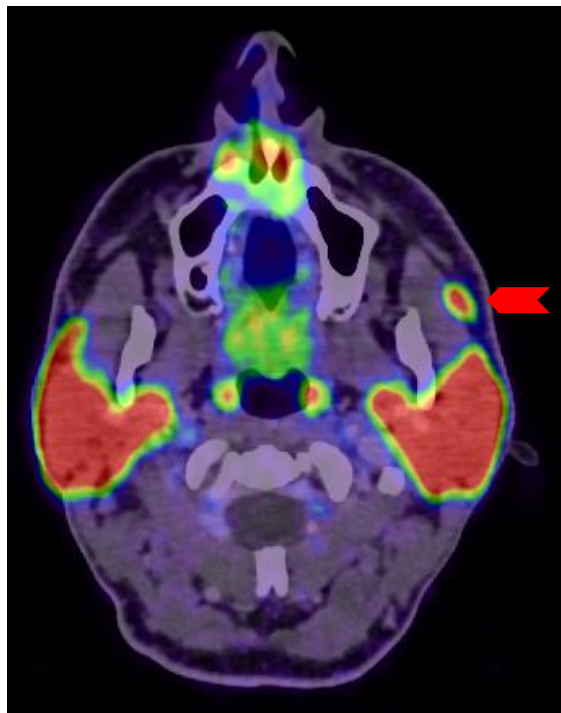
- As with other PET tracers and cancer types, sarcoidosis can be a difficult differential diagnosis
- The most common localization of sarcoidosis is in hilar and mediastinal lymph nodes
- Since this is an uncommon site for metastasis in prostate cancer (and is only expected at an advanced stage), close study of the patient history is also important in this case to assess the probability of such a metastatic pattern



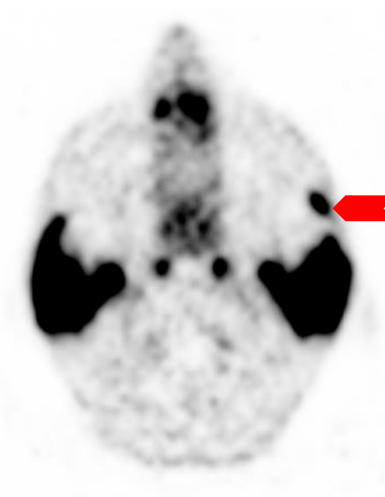
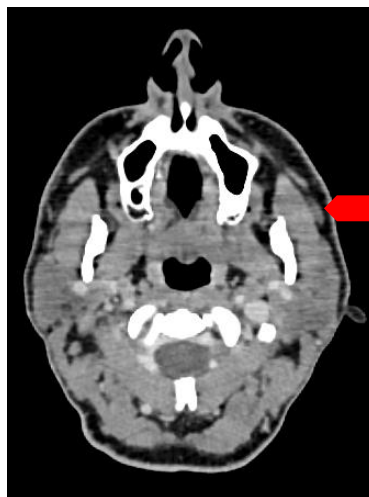

Pitfalls

Accessory Salivary Gland/ Tissue



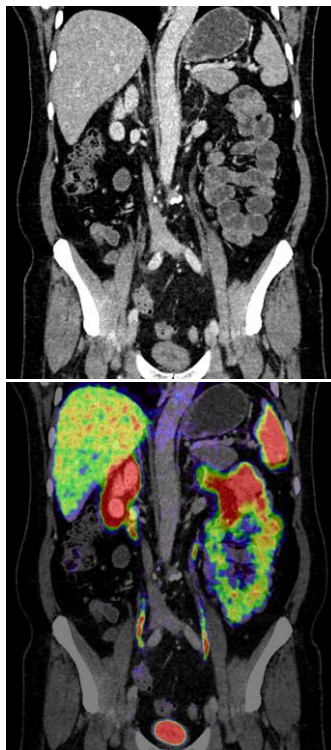
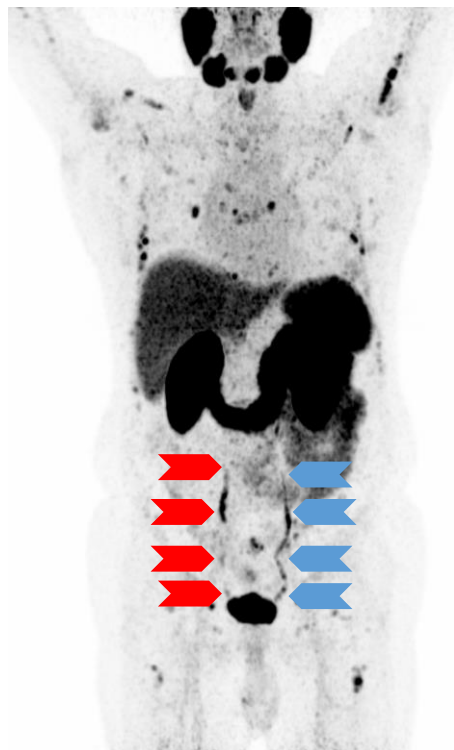- Accessory salivary glands (especially of the parotid gland) are a common normal variant and should not be confused with malignancies of the salivary glands (or soft tissue metastases of prostate carcinoma)



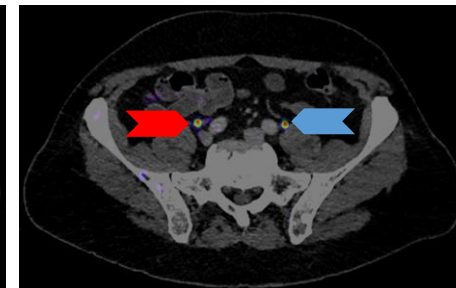
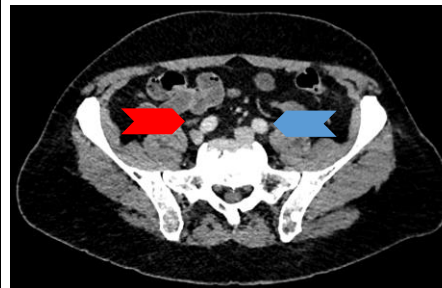


Pitfalls

Urine Activity (Ureter)



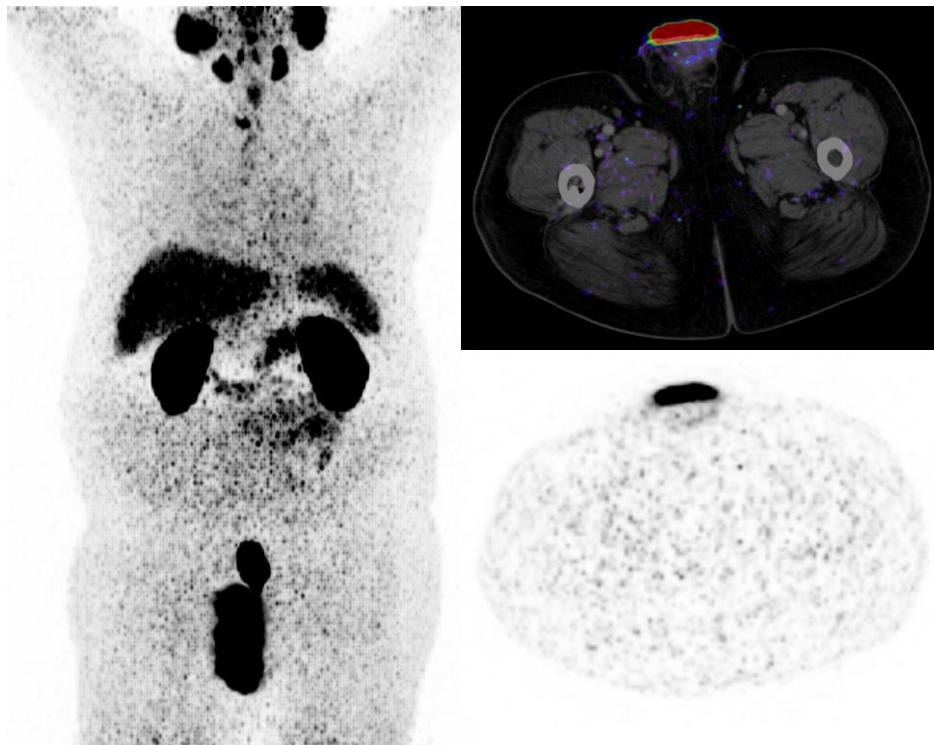
- Due to the variability of presentation (long tubes, focal spots, or not visible at all), the interpretation of the ureters in PET scans can sometimes be tricky
- The following considerations can be helpful to determine the correct categorization:
 - Anatomical correlation on CT
 - A look at the MIP
 - Correlation of the SUVs of the lesion in question, urine, and a tumor lesion



Pitfalls

Urine Contamination

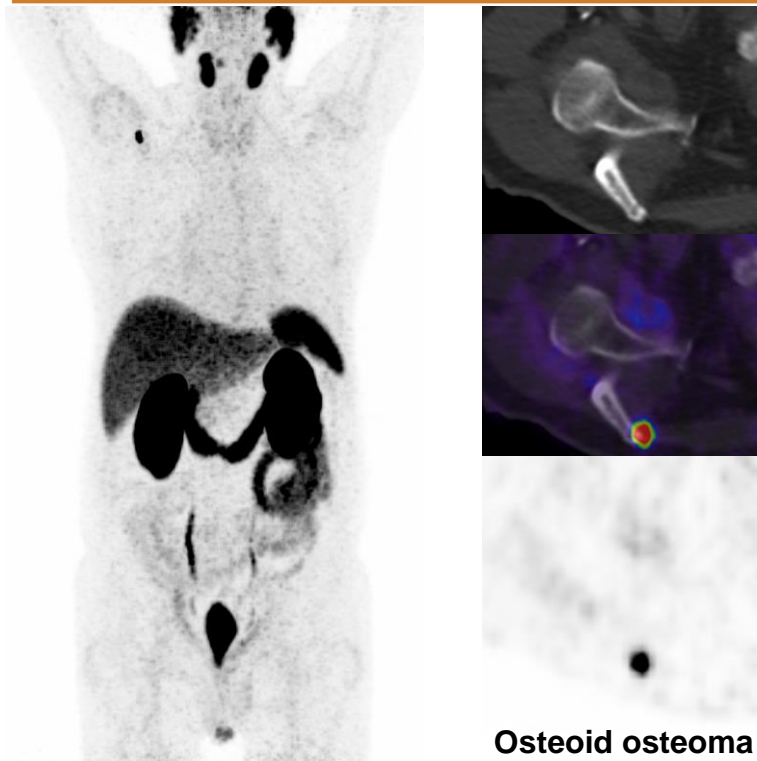
▶ CLICK TO PLAY



- Urine contamination frequently occurs as a result of previous surgical damage to patient continence and use of furosemide
- Normally, this is easy to classify correctly due to the intense SUV_{max} , typical areal and cutaneous distribution in the intimate area and possibly on clothing
- Nevertheless, a careful look at the accumulation is recommended to avoid missing a rare tumor manifestation such as penile metastasis

Pitfalls

Benign Bone Lesions



- Benign bone lesions are often difficult to differentiate from metastases in their uptake behavior. These include, osteoid osteomas, enchondromas, fibromas, hemangiomas, fractures, and degenerative changes (among others)
- In these cases, a comparison with anatomy is particularly important
- To estimate the probability of malignancy, the promise criteria may also be consulted
- For ambiguous lesions, further investigation is strongly recommended (e.g., in case of osteoid osteoma an MRI may be needed)

Self-assessment test

Version 1.0

01/2023 | Locametz_2023_FI_1



Question 1

Which of the following answers is not an on-label indication for the use of gallium (^{68}Ga) gozetotide?

- a) Screening for prostate cancer in male patients over the age of 65
- b) Primary staging of patients with high-risk PCa prior to primary curative therapy
- c) Suspected PCa recurrence in patients with increasing levels of serum prostate-specific antigen (PSA) after primary curative therapy
- d) Identification of patients with PSMA-positive progressive metastatic castration-resistant prostate cancer (mCRPC) for whom PSMA-targeted therapy is indicated

Question 1

Which of the following answers is not an on-label indication for the use of gallium (^{68}Ga) gozetotide?

- a) Screening for prostate cancer in male patients over the age of 65**
- b) Primary staging of patients with high-risk PCa prior to primary curative therapy
- c) Suspected PCa recurrence in patients with increasing levels of serum prostate-specific antigen (PSA) after primary curative therapy
- d) Identification of patients with PSMA-positive progressive metastatic castration-resistant prostate cancer (mCRPC) for whom PSMA-targeted therapy is indicated

Question 2

Which of these organs does not physiologically show an uptake of gallium (^{68}Ga) gozetotide?

- a) Parotid gland
- b) Liver
- c) Brain
- d) Spleen
- e) Kidney

Question 2

Which of these organs does not physiologically show an uptake of gallium (^{68}Ga) gozetotide?

- a) Parotid gland
- b) Liver
- c) **Brain**
- d) Spleen
- e) Kidney

Question 3

What is the ideal uptake time for gallium (^{68}Ga) gozetotide?

- a) 60 seconds
- b) 10 minutes
- c) 60 minutes
- d) 120 minutes
- e) 240 minutes

Question 3

What is the ideal uptake time for gallium (^{68}Ga) gozetotide?

- a) 60 seconds
- b) 10 minutes
- c) **60 minutes**
- d) 120 minutes
- e) 240 minutes

Question 4

What is the target structure of gallium (^{68}Ga) gozetotide?

- a) Prostate-specific antigen (PSA)
- b) Prostate-specific membrane antigen (PSMA)
- c) Somatostatin receptors (SSTR) 2 and 5
- d) Testosterone
- e) Glucose transporter 2 (GLUT2)

Question 4

What is the target structure of gallium (^{68}Ga) gozetotide?

- a) Prostate-specific antigen (PSA)
- b) Prostate-specific membrane antigen (PSMA)**
- c) Somatostatin receptors (SSTR) 2 and 5
- d) Testosterone
- e) Glucose transporter 2 (GLUT2)

Question 5

Which of the following tumor entities could also typically be detected by gallium (^{68}Ga) gozetotide uptake as an incidental finding?

- a) Small cell lung cancer
- b) Neuroendocrine tumor of the pancreas
- c) Medullary thyroid cancer
- d) Hepatocellular cancer
- e) Squamous cell cancer of the penis

Question 5

Which of the following tumor entities could also typically be detected by gallium (^{68}Ga) gozetotide uptake as an incidental finding?

- a) Small cell lung cancer
- b) Neuroendocrine tumor of the pancreas
- c) Medullary thyroid cancer
- d) Hepatocellular cancer**
- e) Squamous cell cancer of the penis

Question 6

The implementation of injection of which drug in the patient administration and scanning protocols of gallium (^{68}Ga) gozetotide can be considered?

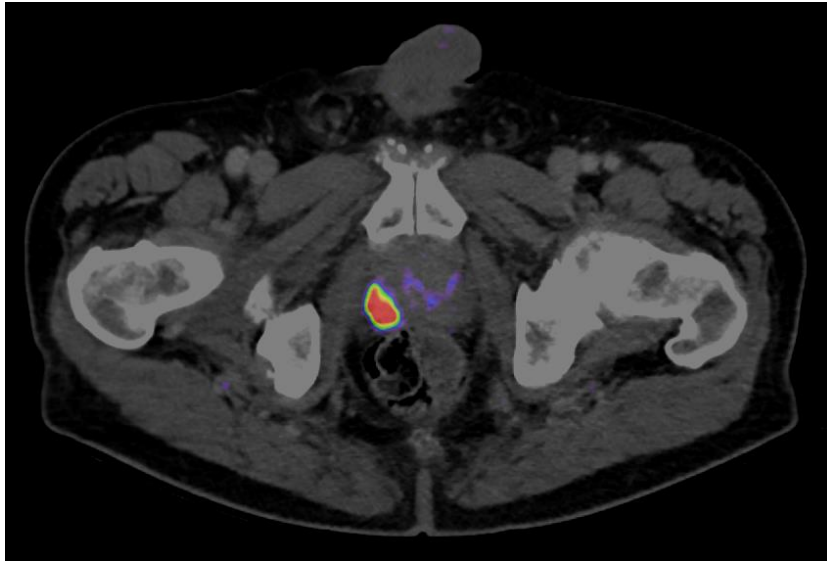
- a) Furosemide
- b) Insulin
- c) Cortisol
- d) Morphium
- e) Tamsulosin

Question 6

The implementation of injection of which drug in the patient administration and scanning protocols of gallium (^{68}Ga) gozetotide can be considered?

- a) **Furosemide**
- b) Insulin
- c) Cortisol
- d) Morphium
- e) Tamsulosin

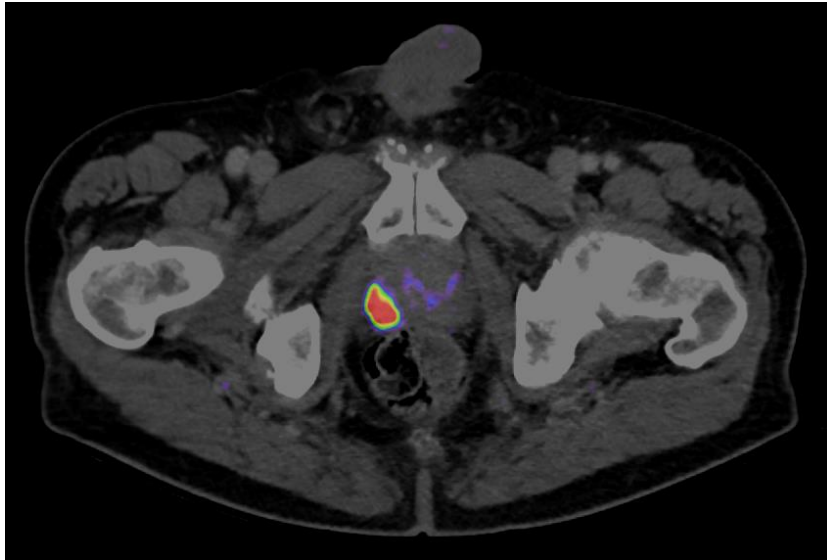
Question 7



What is the most likely cause of the intense tracer accumulation in the right apical sextant of the prostate on the image?

- a) Urine contamination
- b) Bladder prolapse
- c) Unifocal prostate cancer
- d) Accessory salivary gland
- e) Unspecific

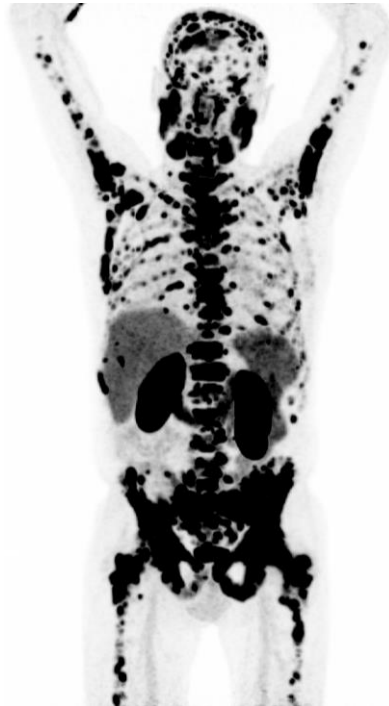
Question 7



What is the most likely cause of the intense tracer accumulation in the right apical sextant of the prostate on the image?

- a) Urine contamination
- b) Bladder prolapse
- c) Unifocal prostate cancer**
- d) Accessory salivary gland
- e) Unspecific

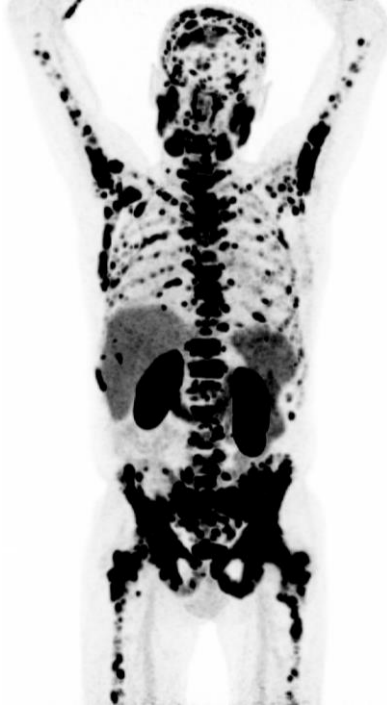Question 8



What is the most plausible explanation for the increased PSMA expression in the skeleton in the imaged MIP?

- a) Solitary bone metastases
- b) Diffuse bone marrow infiltration
- c) Lymphoma as a secondary malignancy
- d) Bone marrow activation
- e) Multiple bone islands

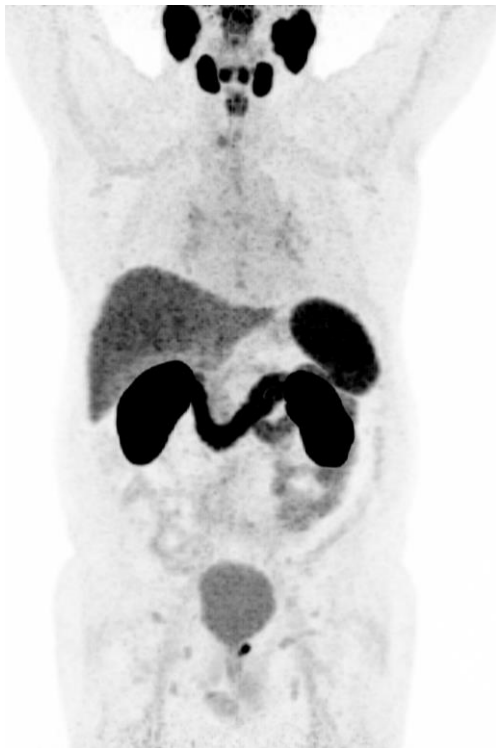Question 8



What is the most plausible explanation for the increased PSMA expression in the skeleton in the imaged MIP?

- a) Solitary bone metastases
- b) Diffuse bone marrow infiltration**
- c) Lymphoma as a secondary malignancy
- d) Bone marrow activation
- e) Multiple bone islands

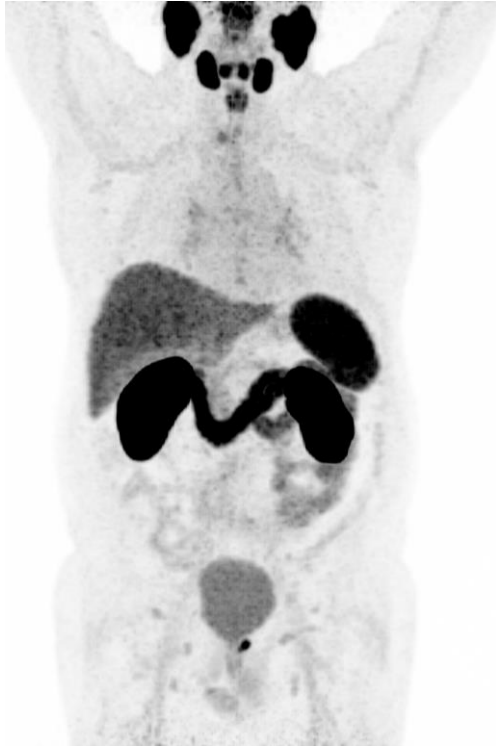Question 9



Following the PROMISE criteria, what PSMA expression score would you give to the local recurrence shown?

- a) 0 (No)
- b) 1 (Low)
- c) 2 (Intermediate)
- d) 3 (High)

Question 9



Following the PROMISE criteria, what PSMA expression score would you give to the local recurrence shown?

- a) 0 (No)
- b) 1 (Low)
- c) 2 (Intermediate)**
- d) 3 (High)

Question 10

What is a common side-effect of the application of gallium (^{68}Ga) gozetotide?

- a) Local radiation necrosis
- b) Anaphylactic shock
- c) Hypertensive crisis
- d) None of the above

Question 10

What is a common side-effect of the application of gallium (^{68}Ga) gozetotide?

- a) Local radiation necrosis
- b) Anaphylactic shock
- c) Hypertensive crisis
- d) None of the above**

Thank you

Part of risk management plan v1.3.

Date of Fimea approval: 17.3.2023

Version 1.0

October 2022 | AAA-NP-GL-0334-22

01/2023 | Locametz_2023_FIEN_1

Locametz® Educational
Material for HCPs
Gallium (^{68}Ga) gozetotide image
interpretation training